

SYNCHRONOUS, METACHRONOUS AND METASTATIC TUMORS OF THE UPPER FEMALE GENITAL TRACT

CORNELIA AMALINEI^{1*}, RALUCA BALAN¹, EDUARD CRAUCIUC¹, OVIDIU TOMA²

Key words: synchronous, metachronous, metastasis, pseudomyxoma peritonei, cytokeratin, PTEN, MI

Abstract: The occasional finding of simultaneous or metachronous multiple primary cancers in the upper genital tract may represent metastasis from one location to another or independent primary tumors. The overall survival of patients with simultaneous primary cancers of the ovary and uterus suggests multifocal rather than metastatic disease. Diagnosis relies upon conventional clinicopathological criteria. The distinction is important because the prognosis and treatment are different. Metastases to the female genital tract occur frequently in the ovary, sometimes the ovarian tumor being primarily manifested although the extragenital tumor remains occult. In perspective, global genetic profiling should determine the potential prognostic relevance of specific molecular alterations, by correlation of profiling data with patient outcome.

INTRODUCTION

The simultaneous or metachronous occurrence of multiple primary cancers in the upper genital tract is well recognized (Woodruff and Julian, 1969; Eifel et al., 1982; Rusell et al., 1985; Ulbright and Roth, 1985; Young et al., 2002; Amalinei et al., 2006) and metastases to the female genital tract occur frequently, the ovary being the most common site (Oliva, 2006).

Simultaneous carcinomas of the uterine corpus and ovary, usually detected as synchronous and less commonly as metachronous tumors, occur in 15 to 20% of ovarian tumors and in approximately 5% of uterine tumors (endometrioid type in the majority of cases) (Irving, 2006). The occasional finding of simultaneous primary tumors in the ovaries and endometrium should not be surprising, as the surface epithelium of the ovary has the same embryologic derivation as the Müllerian duct (Amalinei, 2007) and therefore, in adults, a given carcinogenic stimulus may produce similar epithelial proliferations in both structures (Matias-Guiu et al., 2002). Synchronous and metachronous endometrial and ovarian cancers may be part of familial (hereditary) aggregation of cancers, like mismatch repair genes anomalies, known as Hereditary Non-polyposis colon cancer (HNPCC) and Muir Torre Syndrome and BRCA1 gene mutations resulting in BRCA1 Syndrome (Tavassoli and Devilee, 2002; Amalinei et al., 2006). Ovarian tumors may also spread to the contralateral ovary or even to the cervix (Prat, 2005) and cervical tumors may metastasize to the ovary.

Appendiceal mucinous tumors are often associated with synchronous or metachronous ovarian mucinous tumors, the latter being usually responsible for the clinical presentation (Ronnelt, 2006).

Uterus may be involved either by direct extension (tubal, ovarian, peritoneal or cervical carcinoma) or by metastatic carcinoma. Extragenital carcinomas that frequently involve the uterus include breast, stomach and colon, although the cervix is more commonly involved than the uterine corpus (Oliva, 2006). Secondary involvement of vulva and vagina occurs from primary tumors in other pelvic sites (cervix, endometrium) (Amalinei et al., 2006), uterine choriocarcinoma, colon and rectum, ovary, and urinary bladder or urethra. Metastases to the ovary account for 6-17% of ovarian cancers (Palacios, 2005), originating in colorectum, breast, stomach, cervix, pancreas, appendix, biliary tract (Palacios, 2005), lung, and skin (Oliva, 2006). They should always be considered when evaluating bilateral tumors, as 2/3-3/4 of metastases express bilaterality (Palacios, 2005).

Accurate diagnosis as separate independent primary tumors or as primary tumor associated with its metastasis, and identification the site of origin in secondary tumors has important prognostic implications and is necessary for appropriate staging and treatment. In daily practice, the diagnosis has relied for many years on assessment of conventional histopathologic parameters. Application of molecular analysis in cases showing overlapping or inconclusive features may facilitate the correct diagnosis (Irving, 2006).

RESULTS AND DISCUSSIONS

Synchronous endometrial and ovarian cancers

Synchronous endometrial and ovarian cancers are the most frequent simultaneously occurring genital malignancies. Cancers developing concomitantly in these locations are not infrequently misdiagnosed as metastatic tumors (Woodruff and Julian, 1969). However, the overall survival of these patients suggests multifocal rather than metastatic disease (Woodruff and Julian, 1969), because most of these patients survive without recurrence, a finding compatible with stage I endometrial and ovarian carcinomas (Eifel et al., 1982; Ulbright and

Roth, 1985; Prat et al., 1991), about a third of the cases (14-29%) being independent tumors simultaneously involving both sites (Klemi and Gronroos, 1979; Kline et al., 1990).

Independent primary tumors of low histologic grade, usually of endometrioid type, and with involvement limited to the endometrium and ovary, are associated with favorable outcome, without additional treatment (Zaino et al., 1984). Frequently the ovarian cancer is discovered as an incidental finding and diagnosed at an earlier stage because of the symptomatic endometrial tumor. In contrast, tumors that are metastatic from the uterus to ovary, or from the ovary to uterus, usually carry a poor prognosis and require adjuvant therapy. Occasionally ovarian and uterine tumors are similar but of other cell types, and rarely the histologic type of tumor is different in the two organs (Amalinei et al., 2006). Grade 3 endometrioid carcinoma and malignant mesodermal mixed tumors (Amalinei et al., 1997) are generally primary in one organ and metastatic to the other when detected.

Conventional macroscopic and microscopic parameters in simultaneous uterine and ovarian endometrioid adenocarcinomas are, to date, the most practical criteria for distinguishing independent primary tumors from a primary tumor with metastasis. The conventional clinicopathologic parameters include the following (Woodruff and Julian, 1969; Ulbright and Roth, 1985; Russell et al., 1985; Scully et al., 1998; Young et al., 2002; Prat, 2005; Irving, 2006): stage, tumor size, histologic type, tumor grade, lymphovascular invasion, Fallopian tube involvement, myometrial invasion, unilateral or bilateral ovarian tumor, pattern of ovarian involvement (multinodular growth or ovarian surface implants), presence or absence of coexistent lesions (ovarian endometriosis or a pre-existing adenofibromatous component in the ovarian tumor or atypical endometrial hyperplasia), and follow-up.

Generally, in cases of primary carcinomas in an organ associated with metastasis in the other organ, the primary neoplasm is identified by its larger size or more advanced stage, keeping in mind that metastasis from the endometrium to the ovary occurs more often than the reverse.

Rarely, ovarian spread from an endometrial carcinoma with squamous differentiation takes the form of deposits of keratin or degenerated mature squamous cells associated with a foreign body giant cell response on the ovarian serosal surface. If no viable-appearing tumor cells can be identified in these deposits, this finding does not appear to worsen the prognosis even when the granulomas are also found elsewhere on the peritoneum (Tavassoli and Devilee, 2003).

Isolated histologic features can be misleading, as the depth of myometrial invasion, as some cases with a minimally invasive, or even non-invasive, primary endometrial carcinoma may spread to the ovary but the absence of lymphovascular invasion in the myometrium suggests the extra-uterine tumor dissemination to the ovary by retrograde transtubal migration (Irving, 2006). Consequently, at least two histologic criteria need to be associated (Ulbright and Roth, 1985).

As many as 29% of patients with endometrioid ovarian adenocarcinomas will have associated endometrial cancer (Irving, 2006). Frequently in practice, primary ovarian endometrioid carcinomas metastatic to the endometrium may show direct extension of a high grade ovarian tumor to the serosal aspect of the uterus, with prominent myometrial invasion in the outer half of the myometrial wall and less often, anterograde tubal migration may result in tumor implantation in the endometrium.

Immunohistochemical studies may be helpful for distinguishing between metastatic and independent tumors, as the immunohistochemical profiles of **cytokeratins**, **vimentin**, **CA-125**, and **CA 19.9** are different in more than 50% of independent primary tumors (Deavers et al., 2003; Halperin et al., 2003; Dennis et al., 2005).

Application of molecular analysis may facilitate the diagnosis and may identify specific genetic alterations associated with less aggressive biologic behavior in dual primary uterine and ovarian endometrioid carcinomas. Generally, independent primary tumors will exhibit unique genetic alterations, while a metastatic tumor will have the same genetic alterations as the primary tumor from which it is derived. However, independent primary tumors of the uterus and ovary that have very similar histologic features would be expected to share pathways of tumorigenesis, with field effect resulting in similar genetic alterations. Conversely, metastatic tumors may acquire different molecular profiles from the primary tumor as a consequence of tumor progression (Tavassoli and Devilee, 2003; Irving, 2006).

Demonstration of different patterns of **x-chromosome inactivation** in two simultaneous tumors would indicate a different clonal origin (Fujita et al., 1996). Random x-chromosome inactivation, encountered in up to 50% of invasive cancers and 50% probability of different clonal origin in identical x-chromosome inactivation patterns limitates the utility of this analyse in assessing clonality (Prat, 2002).

Flow cytometry may be useful in the analysis of upper genital tract neoplasia (Amalinei et al., 2008). Analysis by DNA ploidy, by static or flow DNA cytometry may be useful (Pinkel et al., 1998), as identical aneuploid DNA indexes in two carcinomas suggest that one of them is metastatic from the other and different DNA indexes suggest two independent primaries (Prat, 2005). In fact, metastatic tumors, or even different areas of the same tumor may exhibit different DNA indexes, as a consequence of tumor progression (Smit et al., 1988).

Loss of heterozygosity (**LOH**) studies can be useful, concordant LOH patterns in both tumor sites being highly suggestive of a common clonal origin (Shenson et al., 1995; Matias-Guiu et al. 2000; Matias-Guiu et al., 2002; Prat, 2002). Main LOH is evident on 17q, reflecting the inactivation of tumor supressor genes in early carcinogenesis but it may also indicate genetic instability in advanced stages (Lerngauer et al., 1998; Lin et al., 1998). The finding of discordant LOH patterns is less helpful, because different regions of the same tumor can exhibit tumor heterogeneity as the result of selective loss of heterozygosity at two loci in only one of the two tumor sites, in independent primary tumors (Emmert-Buck et al., 1997). Consequently LOH analysis is a valuable analysis in order to evaluate the tumor progression (Prat, 2005).

In endometrial endometrioid carcinomas, the most common molecular alterations are microsatellite instability (MI), *PTEN*, *k-ras*, and the beta-catenin gene (*CTNNB1*) mutations. Endometrioid carcinomas of the ovary can also exhibit these molecular alterations, with a similar frequency of beta-catenin abnormalities and a lower incidence of MI and *PTEN* mutations (Sato et al., 2000; Prat, 2005).

Microsatellite instability (**MI**), a marker of defective DNA mismatch repair, is present in 25-30% of sporadic endometrioid carcinomas of the uterine corpus (Risinger et al., 1993; Caduff et al., 1996; Prat, 2005; Irving, 2006). In such cases, MI most commonly arises as a result of promoter hypermethylation of the mismatch repair gene *hMLH1* (Ellenson, 1999; Gras et al., 2001). This epigenetic phenomenon is likely an early event in endometrial tumorigenesis, as it has been demonstrated in atypical endometrial hyperplasia in the absence of MI, and in the majority of MI-positive endometrial carcinomas (Esteller et al., 1999). In sporadic ovarian carcinomas of endometrioid and clear cell types, the frequency of MI is in the range of 15 to 20% of cases (Catusus et al., 2004; Irving, 2006). MI has also been demonstrated with almost double the frequency in synchronous uterine and ovarian carcinomas, both independent (50% and 33%, respectively) and metastatic (67% and 67%, respectively) (King et al, 1995; Shannon et al, 2003; Irving, 2006). The specific patterns of MI must be closely evaluated, with identical patterns of

MI suggesting a common clonal origin, and distinct patterns of MI in support of independent primary tumors. In the setting of synchronous primary tumors, MI is associated with less aggressive biologic behaviour, independent of tumor grade (Fiumicino et al., 2001; Irving, 2006).

Mutations of *PTEN*, a tumor-suppressor gene isolated from the chromosome 10q23 region, have been reported in a wide range of cancers and commonly in endometrial tumors (Kong et al, 1997; Tashiro et al, 1997), almost exclusively limited to those with endometrioid histology (Risinger et al, 1997; Risinger et al, 1998). Moreover, *PTEN* mutations have been detected in precancerous lesions including atypical endometrial hyperplasia and ovarian endometriotic cysts adjacent to endometrioid carcinomas (Levine et al., 2006). In single endometrioid tumors arising in the uterine corpus and ovary, *PTEN* mutations are present in 30-50% (Bussaglia et al., 2000) and 20% of cases, respectively (Obata et al., 1998; Sato et al., 2000). It has been shown that *PTEN* mutations are also frequently present in both independent uterine and ovarian endometrioid carcinomas (38% and 33%, respectively) and metastatic cases (100% and 83%, respectively) (Irving, 2005). This is likely in part attributable to the high rate of MI, as approximately 50% of tumors with *PTEN* mutations demonstrate co-existent MI (Bussaglia et al., 2000); conversely, MI-positive endometrial carcinomas are more likely to show mutations in the *PTEN* tumor suppressor gene (Irving, 2006). As *PTEN* mutations are so common in these tumors, the presence of a *PTEN* mutation in both tumor sites is not necessarily indicative of a clonal origin (Obata et al., 1998; Ricci et al., 2003; Irving, 2006).

Endometrioid carcinomas of the uterus and ovary are often characterized by mutations of *CTNNB1*, the gene encoding beta-catenin, a critical component of Wnt signaling (Karim et al, 2004). Mutations in *CTNNB1* are associated with abnormal nuclear accumulation of beta-catenin, which can be visualized by immunohistochemistry. *CTNNB1* mutations occur in approximately 25% of endometrioid carcinomas of the uterine corpus (Machin et al., 2002) and from 16% to 54% of ovarian endometrioid carcinomas (Gamallo et al., 1999; Moreno-Bueno et al., 2001). *CTNNB1* mutations are identified in approximately 50% of simultaneous independent primary uterine and ovarian endometrioid carcinomas, but are absent in metastatic tumors (Palacios et al., 1998; Irving et al., 2005), providing evidence that nuclear expression of beta-catenin and/or detection of a *CTNNB1* mutation is more likely to be associated with an independent primary tumor and is a potential prognostic marker of favorable outcomes (Machin et al., 2002; Irving, 2006). Nuclear accumulation of beta-catenin in endometrioid carcinomas of the uterine corpus and ovary tends to be most prominent in squamous morules (Saegusa and Okayasu, 2001), suggesting that activation of the APC/beta-catenin pathway may be responsible for a more differentiated tumor cell phenotype (Mirabelli-Primdahl et al., 1999; Schlosshauer et al., 2000; Palacios et al., 2001; Catusus et al., 2004). Positive nuclear beta-catenin lends additional support to the conventional histopathologic findings, as simultaneous endometrioid carcinomas often shows squamous differentiation (Irving, 2006). In the appropriate histologic context, nuclear immunoreactivity for beta-catenin and/or *CTNNB1* mutations support the diagnosis of independent primary tumors, whereas a membranous pattern of beta-catenin immunoreactivity and an absence of *CTNNB1* mutation support the diagnosis of metastatic tumors (Fujii et al., 2002; Irving, 2006).

Concluding, the combined histopathological and molecular criteria helpful in the determination of primary *versus* metastatic concomitant ovarian and endometrial carcinomas are the following:

Corpus primary with ovarian metastasis shows: large corpus tumor, deep myometrial invasion from endometrium, frequent associated atypical endometrial hyperplasia, histological

types uniform and consistent with corpus primary (Fig. 1), lymphatic or blood vessel invasion in corpus, ovary, or both, direct extension to ovary from corpus tumor/ tumor present in fallopian tube, bilateral and/or multinodular, small ovarian tumor(s), tumor predominant on surface of the ovary (Fig. 2), hilar location, surface implants or combination, frequently associated with a desmoplastic reaction, usually no endometriosis in ovary, spread elsewhere in typical pattern of endometrial carcinoma, aneuploidy with similar DNA indices or diploidy, similar molecular genetic or karyotypic abnormalities in both tumors.

Ovarian primary and corpus metastasis show: large ovarian tumor (> 10 cm), ovarian single unilateral mass (80-90% of cases), predominant within ovarian parenchyma, endometriosis sometimes present in the ovary, histological types uniform and consistent with ovarian primary (complex papillary pattern, cystic glands, possible borderline or benign appearing areas), direct extension to corpus from ovarian primary, predominantly into serosal surface of uterus, tumor present on peritoneal surfaces and sometimes in fallopian tube, lymphatic or blood vessel invasion in corpus, ovary, or both (Fig. 3), small endometrial tumor, atypical hyperplasia of endometrium usually absent, spread elsewhere in typical pattern of ovarian carcinoma, aneuploidy with similar DNA indices or diploidy of both tumors, and similar molecular genetic or karyotypic abnormalities in both tumors.

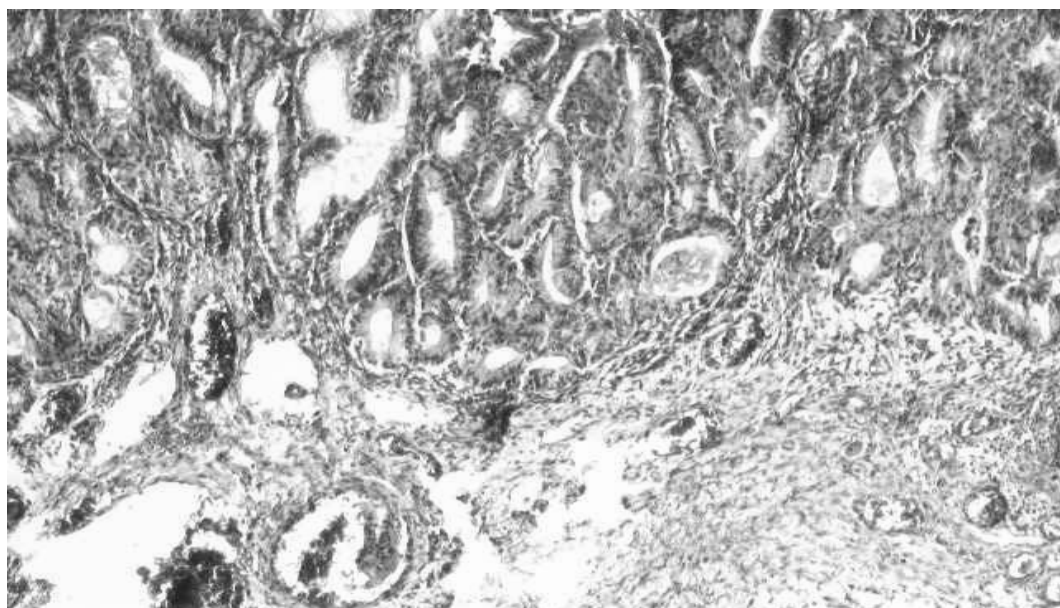


Fig. 1 Endometrioid ovarian carcinoma synchronous with an endometrioid endometrial carcinoma (HE x 100)

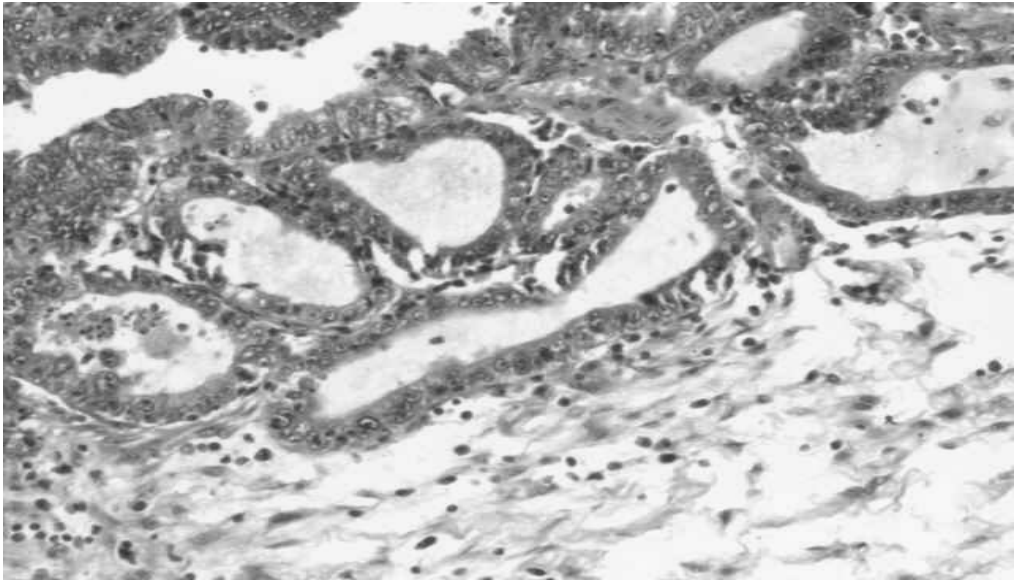


Fig. 2 Surface involvement in endometrioid ovarian carcinoma synchronous with an endometrioid endometrial carcinoma (HE x 200)

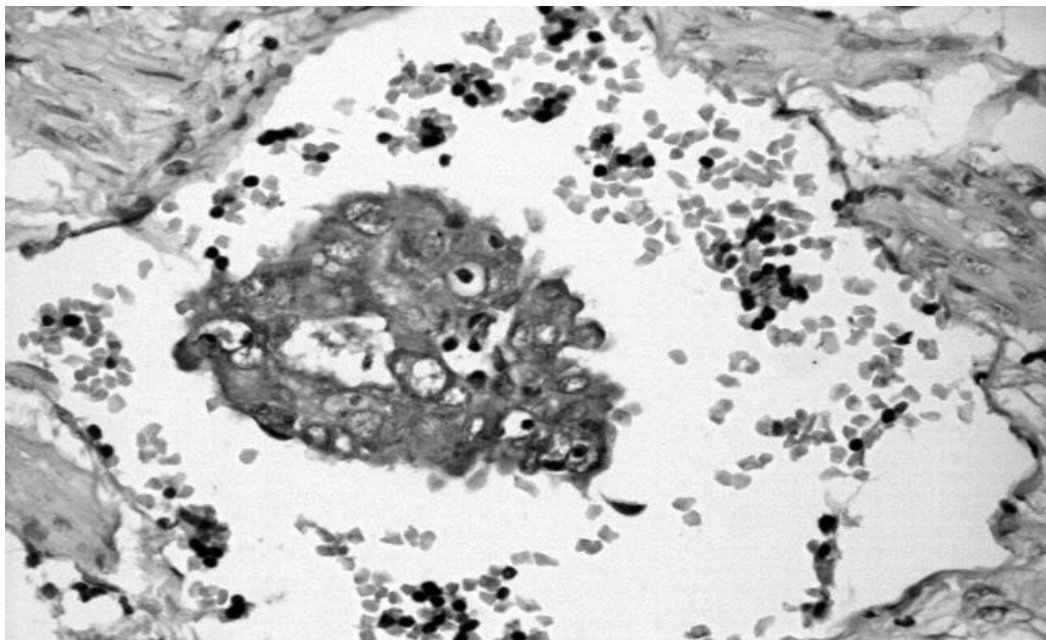


Fig. 3 Miometrial vascular invasion in synchronous endometrial and ovarian carcinomas (cytokeratin cocktail immunohistochemical staining x 200)

Ovarian primary and corpus primary show: usually both tumors confined to primary sites or have spread minimally, and low histological grade, unilateral ovarian tumor (80-90% of cases), usually absent or superficial myometrial invasion, no lymphatic or blood vessel invasion, no surface implants of ovarian tumor, no direct extension of either tumor, frequently associated atypical endometrial hyperplasia, endometriosis sometimes present in ovary, histological types uniform or dissimilar, absence of other evidence of spread of endometrial and ovarian tumor, different ploidy or DNA indices, if aneuploid, of the tumors, dissimilar molecular genetic or karyotypic abnormalities in the tumors, and long survival without recurrence.

Ovarian metastasis and corpus metastasis show: usually no direct extension of tumors, tumor characteristically in endometrial stroma; myometrial invasion may be present, lymphatic or blood vessel invasion frequent in ovary and corpus, atypical hyperplasia of endometrium absent, tumor usually evident outside female genital tract, usually bilateral-ovarian surface involvement, endometriosis absent, and type of tumor inconsistent with or unusual for either organ.

In some cases with massive involvement of both organs or conflicting findings listed in first four categories, assignment of the primary tumor site is based on the initial clinical manifestations (Young et al., 2002).

Endometrioid carcinomas of the uterine corpus and ovary exhibit similar phenotypes, and not surprisingly, similar genotypes as a consequence of shared pathways of tumorigenesis, so molecular testing of one or two biomarkers can result in an equivocal diagnosis. By analyzing copy number for thousands of genes, using comparative genomic hybridization, cDNA or tissue microarrays, a unique tumoral genetic “fingerprint” results (Fig. 4) (Snidjers et al, 2001; Cao et al., 2004; Wa et al., 2005), discriminating primary tumors and its metastases, when comparing to independent tumors of similar histological type.




Fig. 4 Human microarray in endometrial carcinoma

Simultaneous mucinous tumors of the ovary and appendix

Synchronous or metachronous ovarian and appendix mucinous tumors usually have similar histologic appearances (Hart, 2005a; Hart, 2005b; Hart, 2005c; Ronnett, 2006). Primary ovarian tumor with secondary appendiceal metastasis typically spreads to the serosa, mucosa being involved in a lesser degree (Ronnett, 2006).

Appendiceal and ovarian mucinous tumors exhibit the following morphologic types (Ronnett, 2006): low-grade adenomatous mucinous neoplasms (mucinous adenomas) associated with pseudomyxoma peritonei (PMP), mucinous carcinomas (signet ring cell/pure carcinomas; adenocarcinomas with “goblet cell carcinoid-like” patterns, well differentiated glandular adenocarcinomas, mixtures of the above types) associated with peritoneal mucinous carcinomatosis (PMCA) (Ronnett et al., 2001; Ronnett, 2006).

In primary appendiceal adenomatous tumor, adenoma, cystadenoma, villous adenoma, or low-grade mucinous neoplasm (Misdraji et al., 2003), the synchronous mucinous ovarian tumor has both features of a primary borderline mucinous tumor and a secondary mucinous neoplasm.

Although these tumors were considered a long period as independent primaries, during the last two decades, morphologic, immunohistochemical, and molecular genetic studies have demonstrated that in virtually all cases, the appendiceal tumors are primary and the ovarian tumors are secondary both in PMP and PMCA (Young et al., 1991; Prayson et al., 1994; Ronnett et al., 1995; Ronnett et al., 2004; Ronnett, 2006). Thus, pseudomyxoma peritonei (PMP) represents a mucinous ascites derived from a ruptured appendiceal mucinous adenoma not from a borderline mucinous ovarian tumor of intestinal type, as it was initially believed (Rutgers and Scully, 1988), pathologically diagnosed as “disseminated peritoneal adenomucinosis” (DPAM) (Ronnett, 2006) and is almost always initially present when the tumors are found. In patients with PMP, the thorough examination of appendix identifies a primary tumor (Prayson et al., 1994; Young et al., 1991). Rarely separate primary mucinous tumors of the ovary and appendix unassociated with PMP are reported (Kahn and Demopoulos, 1992; Sumithran and Susil, 1992; Seidman et al., 1993a; Guerrieri et al., 1997; Rudzki et al., 2002).

Macroscopic and microscopic characteristics of ovarian tumors suggest their metastatic nature, by bilaterality (33-80%) (Ronnett et al., 1995; Young et al., 1991; Seidman et al., 1993b), in contrast to unilaterality of primary mucinous borderline tumors (90%) (Ronnett et al., 1995; Rodriguez and Prat, 2002; Lee and Young, 2003). The right-sided location dominance suggests direct or transperitoneal spread from the appendiceal tumor (Young et al., 1991; Hart, 2005). In contrast, unilateral primary mucinous tumors of the ovary are evenly distributed (Ronnett et al., 1995; Rodriguez and Prat, 2002; Lee and Young, 2003).

The ovarian tumors are often responsible for the clinical presentation, so they had been interpreted as independent primary ovarian borderline mucinous tumors or carcinomas and were thought to be responsible for PMP and PMCA, not only when an appendiceal tumor had not been identified but even at times when one had been found. The appendiceal tumor is often identified synchronously with the ovarian tumor(s) but sometimes is discovered metachronously or is never identified due to obliteration of the appendix by the tumor (Ronnett, 2006). Ovarian tumors can be large, exceeding 40 cm in maximal dimension and responsible for the clinical presentation, although 1/3-1/2 are less than 10 cm, smaller than most primary mucinous neoplasms (Prayson et al., 1994; Ronnett et al., 1995; Rodriguez and Prat, 2002). Small deposits of mucin and strips of low-grade intestinal-type epithelium on the surface of the ovary until the aspect of a large multicystic mucinous ovarian neoplasm may be observed (Young et al., 1991; Prayson et al.,

1994). Hypermucinous atypical cells, useful for differential diagnosis with a primary borderline mucinous tumor of intestinal type, exhibit tall size, slender aspect, nuclei compressed by abundant intracellular mucin that is continuous with intracystic mucinous secretion, being disposed in strips suspended in pools of dissecting mucin, and composing an aspect of pseudomyxoma ovarii (PO) (Young et al., 1991; Kahn and Demopoulos, 1992; Seidman et al., 1993; Ronnett et al., 1995; Lee and Young, 2003). Extensive PO is an indicator of a secondary tumor (Hart, 2005).

Mucinous borderline tumors are stage I, with a virtually 100% survival, and rupture of primary ovarian mucinous borderline tumors has not been demonstrated to lead to subsequent PMP (Ronnett, 2006).

Advanced stage disease, associated with PMP in approximately 90% of cases, has a significantly worse prognosis (approximately 50% survival). Mucinous tumors arising in ovarian mature cystic teratomas may also lead to PMP (Ronnett, 2006).

Primary ovarian mucinous tumors characteristics are: unilateral, large (>15 cm), lack of surface or superficial cortical tumor, multicystic and/or solid without parenchymal nodules, typically stage I. In contrast, characteristic features of metastatic mucinous carcinomas are: often bilateral, typically smaller (<15 cm) but can be large, tumor involving ovarian surface and/or superficial cortex, nodular pattern with preserved intervening stroma but can be multicystic, presence of extraovarian tumor (peritoneum, omentum) (Oliva, 2006). Problematic features of some metastatic mucinous carcinomas in the ovary that render difficult distinction from primary ovarian mucinous tumors difficult include: occult primary tumor, unilateral large cystic tumor, patterns of invasion simulating “borderline” tumor with intraepithelial carcinoma or confluent glandular pattern of invasive mucinous carcinoma, higher differentiation than the primary tumor, highly differentiated areas simulating a benign mucinous tumor, suggesting origin in the ovary, and virilization suggesting a primary ovarian sex cord-stromal tumor (Oliva, 2006).

The hypothesis of origin of PMP from peritoneum *via* intestinal metaplasia and field effect in cases of multicentric primary mucinous tumors involving appendix, ovary, and peritoneum (Kahn and Demopoulos, 1992; Seidman et al., 1993) is infirmed by unknown primary low-grade mucinous epithelial tumors of the peritoneum (PMP), without associated primary mucinous tumor of the appendix, ovary or other site (Hart, 2005) in contrast to serous tumors.

Immunohistochemical distinction between synchronous ovarian and appendiceal mucinous tumors may be performed by using cytokeratin staining. CK7 is diffusely immunopositive in primary ovarian mucinous tumors (>95%) (Fig. 5), and usually negative in primary appendiceal tumors, excepting a minority of carcinomas (Ronnett and Seidman, 2003). Carcinomas and PMP associated with ovarian cystic teratomas are typically negative for CK7 and positive for CK20, suggesting that they arise from gastrointestinal elements of the teratoma. CK20 is patchy immunopositive in the majority primary ovarian mucinous tumors (70-80%) (Fig. 6) (40-73 %) (Hart, 2005b; Hart, 2005c) and strongly diffusely positive in primary appendiceal tumors (100%) (Guerrieri et al., 1997; Ronnett et al., 1997; Lee and Young, 2003; Baker et al., 2005; Hart, 2005c). Identical staining patterns for CK7, CK18, CK20, CEA, and HAM-56 (CD68) had been reported in synchronous tumors with PMP (Kahn and Demopoulos, 1992; Ronnett et al., 1997). CK immunohistochemical profile in synchronous tumors associated with PMP is similar with that of appendiceal tumors unassociated with PMP, supporting the hypothesis that the ovarian tumor and the PMP develop from the appendiceal mucinous tumor

(Guerrieri et al., 1997; Ronnett et al. 1997). In double primary appendiceal and ovarian tumors, CK profile is discordant (Guerrieri et al., 1997; Ronnett et al., 1997; Vang et al. 2006).

MUC2 and MUC5AC are also useful in diagnosis, being similarly expressed in synchronous appendiceal and ovarian mucinous tumors associated with PMP and in appendiceal mucinous tumors unassociated with PMP. In contrast, primary ovarian mucinous tumors unassociated with PMP show a diffuse expression of MUC5AC (Fig. 7), and occasionally focal MUC-2 positivity in goblet cells adding new support to the theory of appendiceal origin of PMP and ovarian tumors (Hart, 2005).

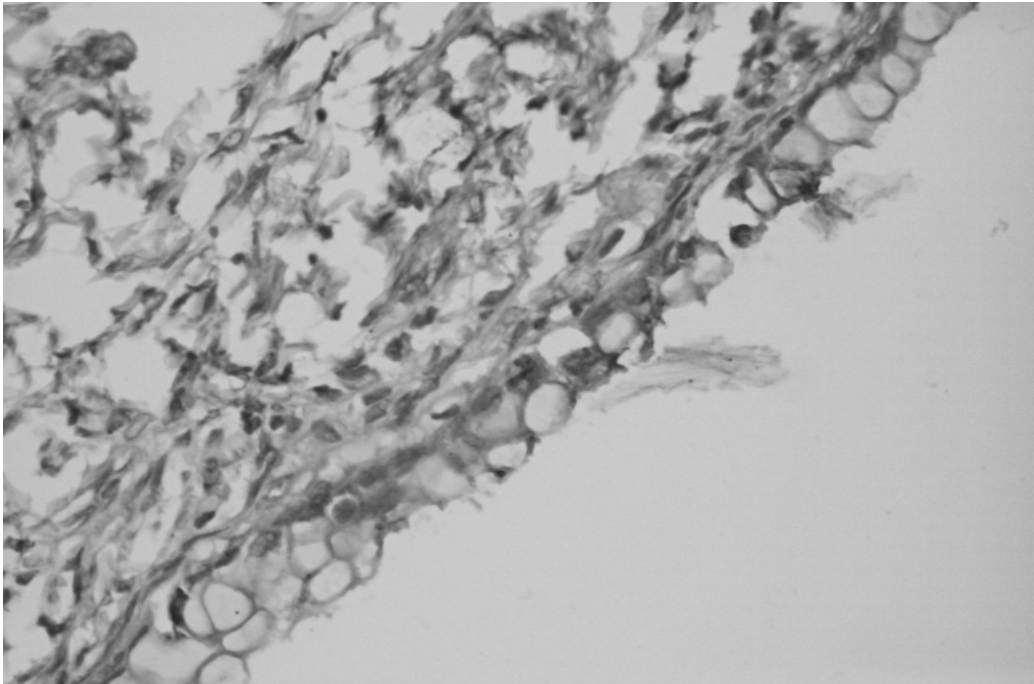


Fig. 5 Primary ovarian mucinous tumor (CK7 diffuse immunopositivity x 200)

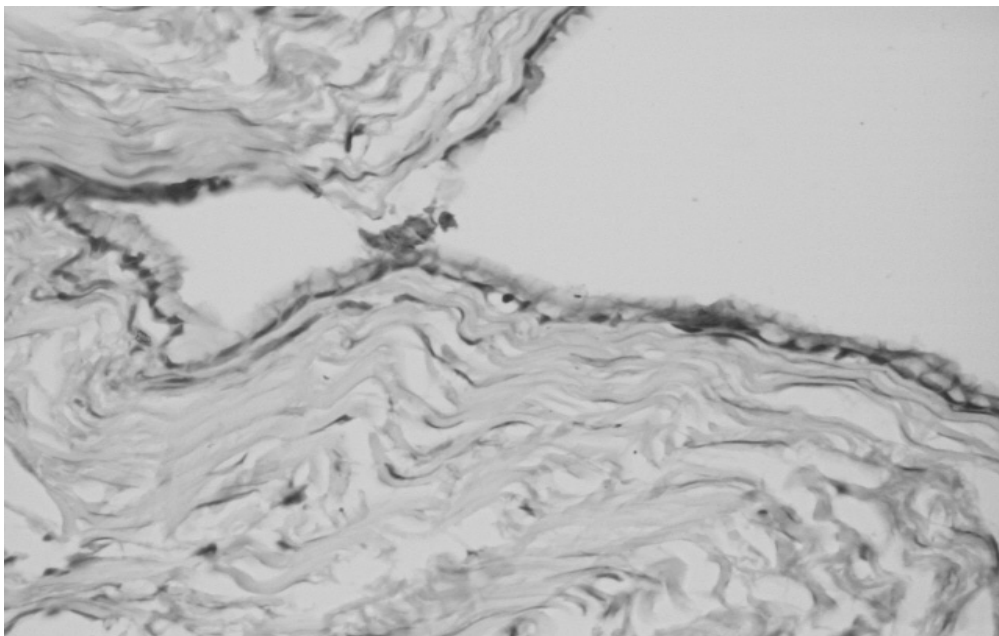


Fig. 6 Primary ovarian mucinous tumor (CK20 patchy immunopositivity x 200)

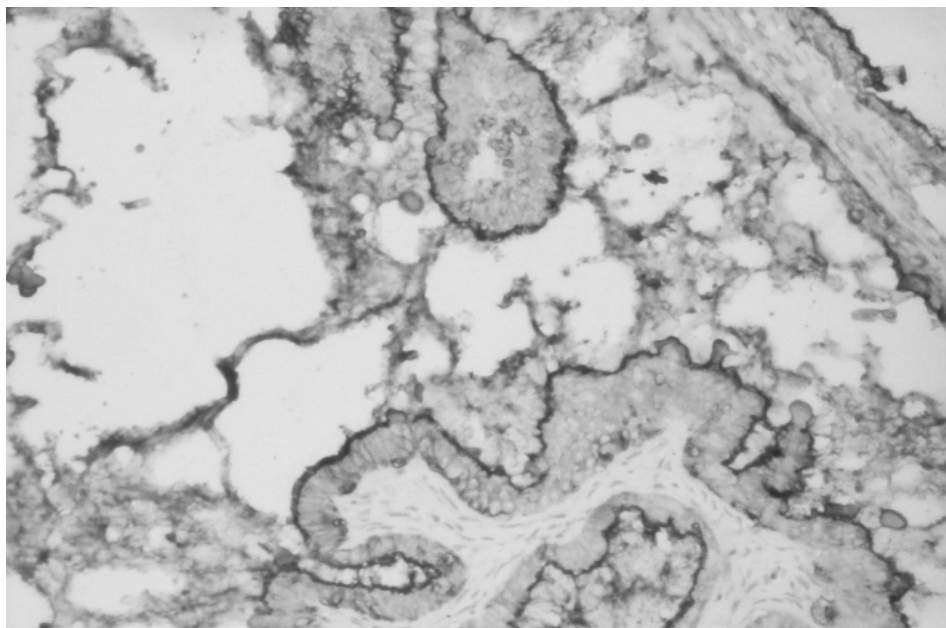


Fig. 7 Primary ovarian mucinous tumor (MUC5AC immunopositivity x 100)

Molecular genetic studies may evidentiate identical K-ras mutations in synchronous appendiceal and ovarian tumors associated with PMP, supporting the idea that they derive from a single site (Cuatrecasas et al., 1996; Szych et al., 1999). Allelic losses (LOH) of chromosomes 5q, 18q, 17p also support the appendiceal origin of PMP and spread to the ovary. Discordant patterns were also noticed, considered as heterogeneity or tumor progression at a metastatic site rather than multifocality (Szych et al., 1999).

Metastatic tumors of the upper female genital tract

Metastases to the female genital tract occur not infrequently, the ovary being the most common site (Mazuret al., 1994; Oliva, 2006). In general, about 15 to 20% of bilateral ovarian tumors will prove to be metastatic (Oliva, 2006). Gross and microscopic features of metastatic and primary ovarian tumors useful for diagnosis are the following (Wilkinson, 2005; Oliva, 2006):

Ovarian metastasis implies: bilateral ovarian involvement, multinodular growth on gross or microscopic examination, surface involvement frequently associated with a desmoplastic reaction or hyalinized fibrous tissue, hilar vascular invasion (primary ovarian tumors, even when high grade, uncommonly exhibit extensive lymphatic or vascular invasion), infiltration of preexistent structures as well as single cells, and different histologic patterns of the tumor in different nodules.

Primary ovarian tumor shows: expansile pattern of invasion, complex papillary pattern, size > 10 cm, smooth external surface, borderline or benign appearing areas at least in most cases, microscopic cystic glands with follicle-like appearance.

The finding of a cystic ovarian tumor is not an infrequent presentation in metastasis and in fact some metastatic tumors are predominantly cystic, as in metastatic colonic cancer, pancreatic carcinoma, endocervical carcinoma, and metastatic carcinoid tumors.

- **Large intestine adenocarcinoma** has a propensity to spread to the ovary, mainly from the rectum or sigmoid colon (77%) (Lash and Hart, 1987). Approximately 3.5% of women with colon carcinoma are found to have ovarian involvement in the course of their disease, presenting with an adnexal mass at the time of diagnosis, without knowing to have a primary tumor in the intestine. Clinical presentation may be of intestinal carcinoma antedating ovarian tumor (50-75% of cases), ovarian tumor found during surgery for an intestinal carcinoma, or initial clinical manifestation is of an ovarian tumor (3-20% of cases), sometimes associated with androgenic symptoms (Young et al., 2002). Up to 45% of metastases from the large intestine are clinically interpreted as primary ovarian carcinomas, as they are frequently large-sized, often predominantly cystic and on microscopic examination closely mimicking a primary ovarian adenocarcinoma (Ronnett et al., 1997). On gross examination, even though they are frequently bilateral, they may be unilateral, and most are >10 cm in largest dimension (Lewis et al, 2006). These tumors have typically a necrotic appearance in the ovary. On microscopic examination they may mimic either primary endometrioid or mucinous carcinomas of the ovary (Young and Scully, 1990), and less frequently some tumors may suggest a primary clear cell carcinoma of the ovary (Young and Hart, 1998). Typical microscopic features in metastatic colon cancer to the ovary include dirty necrosis, composed of eosinophilic masses with nuclear debris within the lumens, focal segmental necrosis of epithelium lining glands and cysts (Lash and Hart, 1987), garland pattern, with ring disposition at the edge of the necrotic material (Lash and Hart, 1987) and glands with severe nuclear atypia and stratification but good preservation of the architecture. The frozen section may suggest the diagnosis of metastasis (Stewart et al., 1997).

In difficult cases the combined use of **CK7** and **CK20** allows the discrimination of most metastatic colorectal carcinomas from ECs of the ovary. Endometrioid adenocarcinomas phenotype is CK7 positive/ CK20 negative, whereas the opposite pertains to colorectal carcinomas, with the exception of right-sided and high-grade colon cancers which more often express CK7. **CEA** may be added to the immunohistochemical panel, as colonic carcinomas are typically CEA positive and approximately 35% of ovarian mucinous carcinomas are CEA negative. Positive CEA and CK20 is a typical phenotype for metastatic intestinal adenocarcinomas in the ovary. In contrast, although not specific, positive **CA-125**, **CK7**, and **HAM56** is typical of a primary ovarian carcinoma (Young et al., 2002). **Cdx-2** shows consistent strong and diffuse nuclear positivity in colorectal carcinomas. However, staining is also seen in ovarian carcinomas, most often in mucinous carcinomas (in up to 93% of cases), and rarely in endometrioid carcinomas. Cdx-2 is an extremely sensitive marker of colorectal cancer, but due to its relative lack of specificity, it is best used in conjunction with other stains (Nucci et al, 2003). **β-catenin** has a relatively limited utility in the diagnosis of metastatic colorectal carcinoma as it is not very sensitive for colon cancer even though ovarian endometrioid and mucinous carcinomas rarely express it (McCluggage and Young, 2005). **P504S** is overexpressed particularly in colorectal and prostate cancers and in their precursor lesions (Oliva, 2006).

- **Breast carcinoma** is one of the most common tumors that metastasizes to the ovary. The frequency of ovarian metastases in women with breast cancer ranges from 10 to 20% at autopsy to about 30% in therapeutic oophorectomy specimens (Oliva, 2006). Ovarian tumor in a woman with breast cancer is more likely to be a new ovarian surface epithelial carcinoma (either poorly differentiated serous or endometrioid carcinoma) and not a metastasis from her breast cancer. Although the ovarian involvement is frequently accompanied by other intraabdominal disease, tumor is confined to the ovary in 15% of the cases. From our experience, lobular carcinoma spreads more commonly to the ovary (Fig. 8) than ductal carcinoma, however, about 75% of ovarian metastases from breast cancer are from ductal cancer (Oliva, 2006). Although lobular carcinomas frequently show typical growth patterns that include tubules, Indian-file cords, clusters, or single cells some being of the signet ring cell type (1.8% of Krukenberg tumor are of breast origin) (Yakushiji et al., 1987), differentiating a primary ovarian carcinoma from a metastatic breast carcinoma may be difficult particularly in women with an inherited breast/ovarian cancer syndrome. Patients with hereditary ovarian cancer belong mostly to the **BRCA 1** group (70%) or **BRCA 2** (20%). Those patients are at a higher risk of developing breast cancer at an earlier age but also ovarian, fallopian tube and peritoneal carcinoma. It is important to differentiate between the two categories of tumors as the 5-year survival rate for patients with primary ovarian carcinoma ranges between 5 and 90%, depending on tumor stage and residual amount of tumor after primary surgery, while patients with metastatic breast cancer to the ovary have a 5-year survival rate of less than 10% (Oliva, 2006).

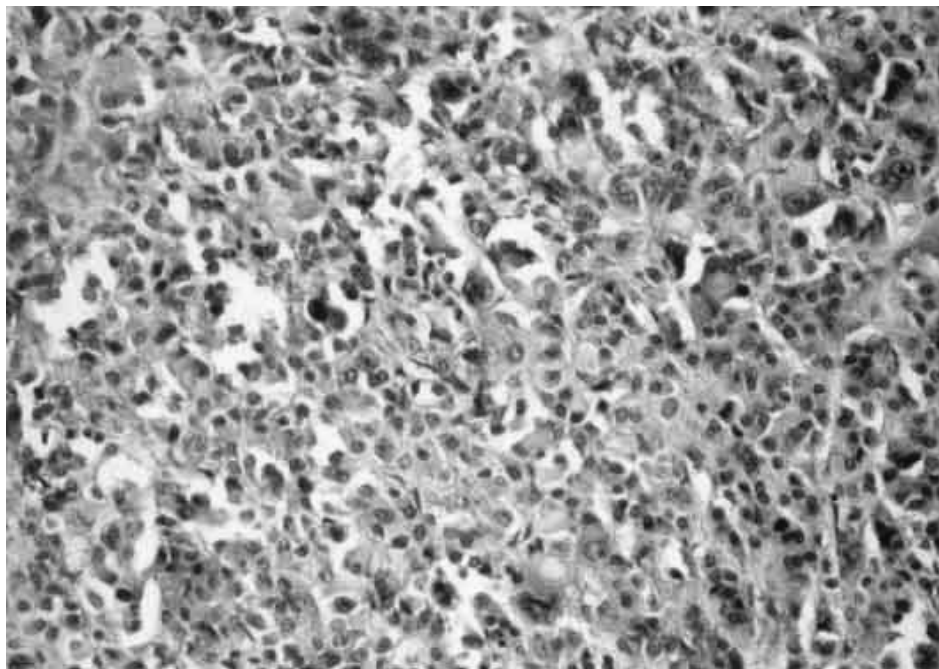


Fig. 8 Ovarian metastasis of a breast carcinoma of lobular type (HE x 200)

The use of differential cytokeratins is not helpful as both breast and ovarian cancers are positive for CK7, but the presence of **CK20** positivity in a metastatic carcinoma is strongly suggestive of a carcinoma of non-breast origin. Gross cystic fluid disease protein 15 (**GCDFP-15**) is a cytoplasmic marker, usually with a paranuclear location, of apocrine differentiation, expressed in the majority of breast carcinomas as well as in tumors of the salivary glands, sweat glands, and prostate. Since salivary and skin adnexal tumors involving the ovary are very rare, a GCDFP-15 positive tumor in the ovary is almost certainly of breast origin. However, a negative GCDFP-15 tumor does not exclude a breast origin, as approximately 30-40% of breast carcinomas are negative for this marker (McCluggage, 2000; McCluggage, 2002). **WT1** expression has been shown to be highest in serous carcinomas (93%) and transitional cell carcinomas (82%), among ovarian cancers, while it is only rarely positive in breast carcinomas. Thus, it may be helpful in distinguishing serous carcinoma from breast carcinoma, especially when the tumor is poorly differentiated (Tornos et al, 2005). Finally **CA-125** may be added to this panel, as most ovarian carcinomas are CA-125 positive while less than 15% of metastatic breast carcinomas to the ovary are only weakly and focally positive (Tornos et al, 2005).

- **Gastric carcinoma:** Krukenberg tumor implies a prominent component of signet ring cells containing abundant mucin typically lying in a background of cellular stroma derived from the ovarian stroma. Most Krukenberg tumors arise in the stomach and more frequently in the pylorus. 2/3 of the primary tumors originate in the stomach, with other primary sites, by order of frequency, being: appendix, colon, breast, small intestine, rectum, gallbladder and urinary bladder (Kiyokawa et al, 2006). Signet ring cell carcinomas metastasize to the ovary more than twice as often as intestinal-type carcinomas (Lerwill and Young, 2006). It is important to note

that some of these patients may have signs or symptoms related to ovarian stromal luteinization particularly during pregnancy, with androgenic manifestations. The primary gastric tumor may be extremely small and sometimes it may be detected years after the diagnosis of the ovarian metastasis. On gross examination the tumors are frequently large, solid and edematous to gelatinous. On microscopic examination, signet ring cells may be inconspicuous or absent in significant areas of the tumor, and some tumors may have a predominant tubular pattern or may show a wide variety of patterns. The differential diagnosis includes a clear cell carcinoma with signet ring cells, primary mucinous carcinoids of the ovary (almost always associated with a dermoid cyst) and in tubular Krukenberg tumors the main differential diagnosis is with a Sertoli Leydig cell tumor. Intestinal-type gastric adenocarcinoma rarely metastasize to the ovary, and in contrast to Krukenberg tumors it seems that patients are older, have a known history of gastric cancer and concomitant widespread disease (Oliva, 2006).

The use of immunohistochemistry in the differential diagnosis of gastric carcinoma *versus* primary ovarian mucinous carcinoma is limited to cytokeratins expression as up to 96% **CK7** positivity and up to 40% **CK20** expression is reported in gastric carcinomas (Oliva, 2006).

- **Pancreaticobiliary carcinoma** accounts for 10% of ovarian metastases that manifest clinically as an ovarian mass, closely mimicking a primary mucinous tumor of the ovary or showing an extremely well differentiated pattern, even benign appearing glands or areas with a borderline appearance. On gross examination they may appear as a unilocular cyst. On microscopic examination they can mimic a benign, borderline mucinous tumor (Garcia et al., 2004), with or without intraepithelial or a mucinous carcinoma. The pancreatic tumors that may metastasize to the ovary are ductal adenocarcinomas and mucinous cystadenocarcinomas (Young and Hart, 1989), the clinical history and search for surface and superficial cortex desmoplastic implants being extremely helpful (Oliva, 2006).

Dpc4, a tumor suppressor gene inactivated by allelic loss in 55% of pancreatic cancers and expressed by lack of immunostaining, was found to be positive in 100% of primary mucinous tumors of the ovary, in the vast majority of colorectal carcinomas (89%), and in 100% of primary appendiceal carcinomas (Oliva, 2006).

Carcinoid tumor accounts for approximately 2% of ovarian metastases (Robboy et al., 1974), originating more commonly from the appendix or small intestine, with more than 1 cm in diameter. Forty percent of women in whom metastases are found at the time of surgery have the carcinoid syndrome and, in most cases, extraovarian metastases are detected (Oliva, 2006). Only 1/3 of patients with primary carcinoids have symptoms or signs related to the carcinoid syndrome and they disappear after surgery. In contrast, in patients with metastatic carcinoids and carcinoid syndrome, the carcinoid syndrome persists, because 90% of the patients have extraovarian metastases (Young et al., 2002). On gross examination, these tumors have frequently a yellow to tan cut-surface and some of them may be predominantly cystic. On microscopic examination, the patterns are insular, trabecular, solid tubular or mucinous, as seen in primary carcinoids of the ovary. Small, round acini may contain a homogenous eosinophilic secretion that may undergo calcification, in the form of psammoma bodies (Young et al., 2002). However, a typical feature is the association with an extensive fibromatous stromal proliferation, closely resembling an ovarian fibroma (Young et al., 2002). Metastatic carcinoids of mucinous type, usually of appendiceal origin, have rounded nests of goblet cells, associated with neuroendocrine cells that may be evidenced by argentic stain, and possible Krukenberg tumor foci and mucinous cysts (Baker et al., 2001; Young and Scully, 1991). Primary ovarian carcinoids are always unilateral, form a single nodule frequently in the wall of a mature cystic teratoma, but they can also be

associated with mucinous tumors or Brenner tumors in the same ovary. In rare occasions where the opposite ovary is enlarged, this is due to the presence of a dermoid cyst or a mucinous tumor. Patients with metastatic carcinoid have a 20% survival rate compared to the 95% survival for patients with primary carcinoids.

Immunohistochemical stains for **chromogranin**, **neuron-specific endolase**, **peptide hormones**, and **serotonin** are helpful only in differentiating carcinoids from other types of tumors with similar microscopic aspect .

Cervical carcinoma: In relatively rare cases of metastatic squamous cell carcinoma from the cervix, the differential diagnosis with a primary squamous cell carcinoma of the ovary is aided by the associated preexistent neoplasm in the latter, such as a dermoid or endometriotic cyst and by the knowledge of the presence of a cervical tumor, in the former. The possible independent primary neoplasms may be considered in rare associations with a squamous cell carcinoma in situ of the cervix (Young et al., 2002). Adenocarcinomas, adenosquamous, glassy cell, small cell, transitional cell carcinomas, and mixed tumors were reported to metastasize to the ovary (Young and Scully, 1991). The vast majority of endocervical adenocarcinomas are high-risk human papillomavirus (HPV)-related neoplasms, characterized by p16 expression and frequent loss of hormone receptor expression, which infrequently metastasize to the ovaries. In a recent series, the ovarian metastases presented in 50% of cases concurrently with the primary endocervical tumors and in 20% prior to diagnosis, 70% of tumors measured more than 10 cm, and they were unilateral in 80% of cases, so were thought to represent independent primary ovarian borderline tumors or well-differentiated endometrioid or mucinous carcinomas (Elishaev et al., 2005).

HPV staining may be helpful in the discrimination of metastasis to the ovary from a primary mucinous tumor. The endocervical and ovarian tumors are positive for either HPV 16 or HPV 18. *In situ* hybridization for HPV DNA and reverse transcriptase *in situ* polymerase chain reaction for HPV RNA have shown concordance of HPV expression, either 16 or 18, in women with metastatic cervical cancer to extraovarian sites, supporting the HPV testing value in identifying metastatic cervical carcinoma (Oliva, 2006). **p16**, a tumor suppressor gene that plays an important role in the regulation and differentiation of the cell cycle, is a reliable surrogate marker for HPV, showing a diffusely positive pattern in metastatic ovarian carcinomas arising in endocervix and absent/limited expression of **ER** and **PR**, in most cases (Elishaev et al., 2005).

- **Lung carcinoma:** Despite the fact that lung carcinoma is common and well known to metastasize widely, ovarian spread from primary lung carcinoma accounts for 0.4%, nonassociated with other foci of intraabdominal spread, indicating the propensity for isolated ovarian spread. Ovarian tumors may be detected up to 26 months before the lung cancer, and small cell carcinoma is the most common subtype to be associated with ovarian manifestations (44%), followed by adenocarcinomas (34%), and large cell carcinomas (16%) (Irving and Young, 2005). The differential diagnosis of small cell carcinoma includes small cell carcinomas of the ovary and mediastinal small cell carcinomas (Eichhorn et al., 1993).

TTF-1, a specific and sensitive marker of most lung adenocarcinomas including bronchioloalveolar adenocarcinoma (non-mucinous type) as well as at least 50% of lung small cell carcinomas, may be used to aid in this differential diagnosis. TTF-1 expression in lung metastases from primary tumors in the colon, breast, stomach, endometrium, and ovary is negative. An adenocarcinoma of pulmonary origin should be strongly considered when a metastatic adenocarcinoma involving the ovary shows TTF-1 positivity. Only one small cell carcinoma of the cervix has been reported to be positive for TTF-1 (Oliva, 2006), so TTF-1 may

be helpful in the rare differential diagnosis of hypercalcemic small cell carcinoma of the ovary and small cell carcinoma metastatic to the ovary.

-Malignant melanoma arises in the skin or occasionally elsewhere, as the choroid, may spread to the ovary, most frequently (95% of cases) as bilateral tumors, approximately 50% of the patients having extraovarian metastases, usually within the pelvis and upper abdomen (Young et al., 2002). The microscopic aspect is that of multiple nodules, with large cells containing abundant eosinophilic cytoplasm (Young and Scully, 1991), rarely with small cells with scanty cytoplasm or spindle cells (Young et al., 2002). Follicle-like spaces observed in 40% of cases may mimic a juvenile granulosa cell tumor (Pavelic et al., 1991; Young and Scully, 1991). Discrete rounded aggregates with a nevoid appearance, prominent nucleoli, cytoplasmic pseudoinclusions, presence of melanin pigment may be helpful for diagnosis (Fitzgibbons et al., 1987; Young et al., 2002). Rare primary melanoma may arise in the wall of a dermoid cyst, sometimes associated with junctional activity beneath the squamous lining of the cyst, or it is associated with struma ovarii (Young et al., 2002). Amelanotic metastatic melanoma may resemble a lipid-poor steroid cell tumor or a pregnancy luteoma, melanin being confused with lipochrome pigment.

Immunohistochemistry for **S-100 protein** and **HMB-45** and negative staining for keratins and other specific antigens may be useful in differential diagnosis (Young et al., 2002).

-Miscellaneous ovarian metastases are reported in literature, arising from the urinary tract, as renal cell carcinoma, signet-ring cell bladder carcinomas, transitional cell carcinomas, adrenal neuroblastoma, visceral or soft tissue sarcomas, mainly diagnosed as rhabdomyosarcoma, hepatocellular carcinoma (confused with primary hepatoid yolk sac tumor, in younger patients and with metastatic hepatoid tumors of the ovary, from the stomach and the lung, in postmenopausal patients) (Young et al., 1992), thyroid carcinomas, parathyroid carcinomas, and tumors of the central nervous system and cranium (Young et al., 2002). Occasionally a metastatic tumor involves an ovary with a preexistent primary ovarian tumor (Hines et al., 1976; Smale, 1980; Yakushiji et al., 1987; Young et al., 2002).

CONCLUSIONS

Traditional histopathologic features still remain the most reliable criteria to discriminate primary *versus* metastasis in synchronous and metachronous tumors of the upper female genital tract. Molecular analysis may be an adjuvant tool, in coroboration with a panel of histopathological characteristics.

In perspective, global genetic profiling of simultaneous female genital tract tumors should expand and perfectionate the accurate diagnosis of these tumors as independent primaries or metastases and determine the potential prognostic relevance of specific molecular alterations, by correlation of profiling data with patient outcome.

REFERENCES

- Amalinei C, Caruntu ID, Balan R, Cianga C, Cianga P, 2008. Contribution of immunohistochemistry and flow-cytometry in the study of endometrial pathology, *Rev Med Chir Soc Med Nat Iasi*. 112(2): 437-448.
- Amalinei C, Caruntu ID, Balan R, Cotutiu C, Badescu M, 1997. Carcinosarcoma of the corpus uteri- a case report, *Rev Med Chir Soc Med Nat Iasi*. 101(1-2): 213-217.
- Amalinei C, R. Balan R, Ivan L, Socolov R, Socolov D, Cotutiu C, 2006. Multiple primary malignant neoplasms- case report, *Central European Journal of Medicine*. 1 (1): 87-98.
- Amalinei C. Morphogenesis and differentiation of the female genital tract. Genetic determinism and epithelium-stromal interactions, 2007. *Rev Med Chir Soc Med Nat Iasi*. 111(1):200-209.
- Baker PM, Oliva E, 2005. Immunohistochemistry as a tool in the differential diagnosis of ovarian tumors: an update. *Int J Gynecol Pathol*. 24(1):39-55.

- Baker PM, Oliva E, Young RH, Talerman A, Scully RE, 2001. Ovarian mucinous carcinoids including some with a carcinomatous component: a report of 17 cases. *Am J Surg Pathol* 25(5):557-568.
- Bussaglia E, del Rio E, Matias-Guiu X, Prat J, 2000. PTEN mutations in endometrial carcinomas. A molecular and clinicopathologic analysis of 38 cases. *Hum Pathol*. 31 (3):312-317.
- Caduff RF, Johnston CM, Svoboda-Newman SM, Poy EL, Merajver SD, Frank TS, 1996. Clinical and pathological significance of microsatellite instability in sporadic endometrial carcinoma. *Am J Pathol*. 148 (5):1671-1678.
- Cao QJ, Belbin T, Socci N, Balan R, Prystowsky MB, Childs G, Jones JG, 2004. Distinctive gene expression profiles by cDNA microarrays in endometrioid and serous carcinomas of the endometrium. *Int J Gynecol Pathol*. 23(4):321-9.
- Catusas L, Bussaglia E, Rodríguez I, Gallardo A, Pons C, Irving JA, Prat J, 2004. Molecular genetic alterations in endometrioid carcinomas of the ovary: similar frequency of beta-catenin abnormalities but lower rate of microsatellite instability and PTEN alterations than in uterine endometrioid carcinomas. *Hum Pathol*. 35(11):1360-1368.
- Catusas L, Machin P, Matias-Guiu X, Prat J. Microsatellite instability in endometrial carcinomas: clinicopathologic correlations in a series of 42 cases, 1998. *Hum Pathol*. 29(10):1160-1164.
- Cuatrecasas M, Matias-Guiu X, Prat J, 1996. Synchronous mucinous tumors of the appendix and the ovary associated with pseudomyxoma peritonei. *Am J Surg Pathol*. 20(6):739-746.
- Deavers MT, Malpica A, Silva EG, 2003. Immunohistochemistry in gynecological pathology. *Int J Gynecol Cancer*. 13(5):567-79.
- Dennis JL, Hvidsten TR, Wit EC, Komorowski J, Bell AK, Downie I, Mooney J, Verbeke C, Bellamy C, Keith WN, Oien KA, 2005. Markers of adenocarcinoma characteristic of the site of origin: development of a diagnostic algorithm. *Clin Cancer Res*. 11(10):3766-3772.
- Eichhorn JH, Young RH, Scully RE, 1993. Non-pulmonary small cell carcinomas of extragenital origin metastatic to the ovary: a report of seven cases. *Cancer* 71(1): 177-186
- Eifel P, Hendrickson M, Ross J, Ballon S, Martinez A, Kempson R, 1982. Simultaneous presentation of carcinoma involving the ovary and the uterine corpus. *Cancer*. 50 (1):163-170.
- Elishaev E, Gilks CB, Miller D, Srodon M, Kurman R, Ronnett BM, 2005. Synchronous and metachronous endocervical and ovarian neoplasms: evidence supporting interpretation of the ovarian neoplasms as metastatic endocervical adenocarcinomas simulating primary ovarian surface epithelial neoplasms. *Am J Surg Pathol*. 29 (3):281-94.
- Ellenson LH, 1999. hMLH1 promoter hypermethylation in microsatellite instability-positive endometrial carcinoma. Cause or consequence? *Am J Pathol*. 155(5):1399-1402.
- Emmert-Buck MR, Chuaqui R, Zhuang Z, Nogales F, Liotta LA, Merino MJ, 1997. Molecular analysis of synchronous uterine and endometrioid tumors of the ovary and endometrium. *Int J Gynecol Pathol*. 16(2):143-148.
- Esteller M, Catusas L, Matias-Guiu X, Mutter GL, Prat J, Baylin SB, Herman JG, 1999. hMLH-1 promoter hypermethylation is an early event in human endometrial tumorigenesis. *Am J Pathol*. 155(5):1767-1772.
- Fitzgibbons PL, Martin SE, Simmons TJ, 1987. Malignant melanoma metastatic to the ovary. *Am J Surg Pathol*. 11(12):959-964
- Fiumicino S, Ercoli A, Ferrandina G, Hess P, Raspaglio G, Genuardi M, Rovella V, Bellacosa A, Cicchillitti L, Mancuso S, Bignami M, Scambia G, 2001. Microsatellite instability is an independent indicator of recurrence in sporadic stage I-II endometrial adenocarcinoma. *J Clin Oncol*. 19(4):1008-1014.
- Fujii H, Matsumoto T, Yoshida M, Furugen Y, Takagaki T, Iwabuchi K, Nakata Y, Takagi Y, Moriya T, Ohtsuji N, Ohtsuji M, Hirose S, Shirai T, 2002. Genetics of synchronous uterine and ovarian endometrioid carcinoma: combined analyses of loss of heterozygosity, PTEN mutation, and microsatellite instability. *Hum Pathol*. 33(4):421-428.
- Fujita M, Enomoto T, Wada H, Inoue M, Okudaira Y, Shroyer KR, 1996. Application of clonal analysis. Differential diagnosis for synchronous primary ovarian and endometrial cancers and metastatic cancer. *Am J Clin Pathol*. 105(3):350-359.
- Gamallo C, Palacios J, Moreno G, Calvo de Mora J, Suárez A, Armas A., 1999. Beta-catenin expression pattern in stage I and II ovarian carcinomas: relationship with beta-catenin gene mutations, clinicopathological features, and clinical outcome. *Am J Pathol*. 155(2):527-536.
- García A, De la Torre J, Castellvi J, Gil A, López M., 2004 Ovarian metastases caused by cholangiocarcinoma: a rare Krukenberg's tumour simulating a primary neoplasm of the ovary: a two-case study. *Arch Gynecol Obstet*. 270(4):281-284.
- Gras E, Catusas L, Argüelles R, Moreno-Bueno G, Palacios J, Gamallo C, Matias-Guiu X, Prat J., 2001. Microsatellite instability, MLH1 promoter hypermethylation, and frameshift mutations at coding mononucleotide repeat microsatellites in ovarian tumors. *Cancer*. 92(11):2829-2836.
- Guerrieri C, Fränlund B, Fristedt S, Gillooley JF, Boeryd B, 1997. Mucinous tumors of the vermicular appendix and ovary, and pseudomyxoma peritonei: histogenetic implications of cytokeratin 7 expression. *Hum Pathol* 28(9):1039-1045.
- Halperin R, Zehavi S, Hadas E, Habler L, Bukovsky I, Schneider D, 2003. Simultaneous carcinoma of the endometrium and ovary vs. endometrial carcinoma with ovarian metastases: a clinical and immunohistochemical determination. *Int J Gynecol Cancer*. 13(1):32-37.

- Hart WR, 2005a. Diagnostic challenge of secondary (metastatic) ovarian tumors simulating primary endometrioid and mucinous neoplasms. *Pathol Int.* 55(5):231-243.
- Hart WR, 2005b. Mucinous tumors of the ovary: a review. *Int J Gynecol Pathol.* 24(1):4-25.
- Hart WR, 2005c. Simultaneous mucinous tumors of the ovary and appendix. In: *European Congress of Pathology. Carrefour Pathologie 2005. Update in Pathology, Paris*, pp. 162- 165
- Hines JR, Gordon RT, Widger C, Kolb T, 1976. Cystosarcoma phylloides metastatic to a Brenner tumor of the ovary. *Arch Surg* 111(3):299-300.
- Irving J, Young RH, 2005. Lung carcinoma metastatic to the ovary: A clinicopathologic study of 32 cases emphasizing their morphologic spectrum and problems in differential diagnosis. *Am J Surg Pathol.* 29(8):997-1006.
- Irving JA, 2006, Simultaneous endometrioid adenocarcinomas of the uterine corpus and ovaries, In: *CD Symposia IAP, Montreal*
- Irving JA, Catusus L, Gallardo A, Bussaglia E, Romero M, Matias-Guiu X, Prat J., 2005. Synchronous endometrioid carcinomas of the uterine corpus and ovary: alterations in the b-catenin (CTNNB1) pathway are associated with independent primary tumors and favorable prognosis. *Hum Pathol.* 36(6):605-619.
- Kahn MA, Demopoulos RI, 1992. Mucinous ovarian tumors with pseudomyxoma peritonei: A clinicopathological study. *Int J Gynecol Pathol.* 11(1):15-23.
- Karim R, Tse G, Putti T, Scolyer R, Lee S., 2004. The significance of the Wnt pathway in the pathology of human cancers. *Pathology.* 36(2):120-8.
- King BL, Carcangiu ML, Carter D, Kiechle M, Pfisterer J, Pflaiderer A, Kacinski BM., 1995. Microsatellite instability in ovarian neoplasms. *Br J Cancer.* 72(2):376-382.
- Kiyokawa T, Young RH, Scully RE, 2006. Krukenberg tumors of the ovary: a clinicopathologic analysis of 120 cases with emphasis on their variable pathologic manifestations. *Am J Surg Pathol.* 30(3):277-299.
- Klemi PJ, Grönroos M, 1979. Endometrioid carcinoma of the ovary. A clinicopathologic, histochemical, and electron microscopic study. *Obstet Gynecol.* 53(5): 572-579.
- Kline RC, Wharton JT, Atkinson EN, Burke TW, Gershenson DM, Edwards CL, 1990. Endometrioid carcinoma of the ovary: retrospective review of 145 cases. *Gynecol Oncol.* 39(3):337-346.
- Kong D, Suzuki A, Zou TT, Sakurada A, Kemp LW, Wakatsuki S, Yokoyama T, Yamakawa H, Furukawa T, Sato M, Ohuchi N, Sato S, Yin J, Wang S, Abraham JM, Souza RF, Smolinski KN, Meltzer SJ, Horii A., 1997. PTEN is frequently mutated in primary endometrial carcinomas. *Nat Genet.* 17(2):143-144.
- Lash RH, Hart WR, 1987. Intestinal adenocarcinomas metastatic to the ovaries. A clinicopathological evaluation of 22 cases. *Am J Surg Pathol.* 11(2): 114-121.
- Lee KR, Young RH, 2003. The distinction between primary and metastatic mucinous carcinomas of the ovary: gross and histologic findings in 50 cases. *Am J Surg Pathol.* 27(3):281-292.
- Lerngauer C, Kinzler KW, Vogelstein B, 1998. Genetic instabilities in human cancers. *Nature.* 396 (6712): 643-649
- Lerwill MF, Young RH, 2006. Ovarian metastases of intestinal-type gastric carcinoma: A clinicopathologic study of 4 cases with contrasting features to those of the Krukenberg tumor. *Am J Surg Pathol.* 30(11): 1382-1388.
- Levine RL, Cargile CB, Blazes MS, van Rees B, Kurman RJ, Ellenson LH., 1998. PTEN mutations and microsatellite instability in complex atypical hyperplasia, a precursor lesion to uterine endometrioid carcinoma. *Cancer Res.* 58(15):3254-3258.
- Lewis MR, Deavers MT, Silva EG, Malpica A, 2005. Ovarian involvement by metastatic colorectal adenocarcinoma: still a diagnostic challenge. *Am J Surg Pathol* 2006;30(2):177-184.
- Lin WM, Forgacs E, Warshal DP, Yeh IT, Martin JS, Ashfaq R, Muller CY., 1998. Loss of heterozygosity and mutational analysis of the PTEN/MMAC1 gene in synchronous endometrial and ovarian carcinomas. *Clin Cancer Res.* 4(11):2577-2583.
- Machín P, Catusus LI, Pons C, Muñoz J, Matias-Guiu X, Prat J., 2002. CTNNB1 mutations and beta-catenin expression in endometrial carcinomas. *Hum Pathol.* 33(2):206-211.
- Matias-Guiu X, Bussaglia E, Catusus LL, Lagarda H, Gras E, Machin P, Prat J., 2000. Loss of heterozygosity and mutational analysis of the PTEN/MMAC1 gene in synchronous endometrial and ovarian carcinomas (Letter to the editor). *Clin Cancer Res.* 6(4):1598-1600.
- Matias-Guiu X, Lagarda H, Catusus L, Bussaglia E, Gallardo A, Gras E, Prat J., 2002. Clonality analysis in synchronous or metachronous tumors of the female genital tract. *Int J Gynecol Pathol.* 21(3):205-211.
- Mazur MT, Hsueh S, Gersell DJ, 1984. Metastases to the female genital tract. Analysis of 325 cases. *Cancer.* 53(9):1978-1984.
- McCuggage WG, 2000. Recent advances in immunohistochemistry in the diagnosis of ovarian neoplasms. *J Clin Pathol.* 53(5):327-334.
- McCuggage WG, 2002. Recent advances in immunohistochemistry in gynecological pathology. *Histopathology.* 40(4):309-326.

- McCluggage WG, Wilkinson N, 2005. Metastatic neoplasms involving the ovary: a review with an emphasis on morphological and immunohistochemical features. *Histopathology*. 47:231-47.
- McCluggage WG, Young RH, 2005. Immunohistochemistry as a diagnostic aid in the evaluation of ovarian tumors. *Semin Diagn Pathol*. 22(1):3-32
- Mirabelli-Primdahl L, Gryfe R, Kim H, Millar A, Luceri C, Dale D, Holowaty E, Bapat B, Gallinger S, Redston M., 1999. Beta-catenin mutations are specific for colorectal carcinomas with microsatellite instability but occur in endometrioid carcinoma irrespective of mutator pathway. *Cancer Res*. 59(14):3346-3351.
- Misdraji J, Yantiss RK, Graeme-Cook FM, Balis UJ, Young RH, 2003. Appendiceal mucinous neoplasms: a clinicopathologic analysis of 107 cases. *Am J Surg Pathol*. 27(8):1089-1103.
- Moreno-Bueno G, Gamallo C, Pérez-Gallego L, de Mora JC, Suárez A, Palacios J., 2001. Beta-catenin expression pattern, beta-catenin gene mutations, and microsatellite instability in endometrioid ovarian carcinomas and synchronous endometrial carcinomas. *Diagn Mol Pathol*. 10(2):116-122.
- Nucci MR, Castrillon DH, Bai H, Quade BJ, Ince TA, Genest DR, Lee KR, Mutter GL, Crum CP., 2003. Biomarkers in diagnostic obstetric and gynecologic pathology: a review. *Adv Anat Pathol*. 10(2):55-68.
- Obata K, Morland SJ, Watson RH, Hitchcock A, Chenevix-Trench G, Thomas EJ, Campbell IG., 1998. Frequent PTEN/MMAC mutations in endometrioid but not serous or mucinous epithelial ovarian tumors. *Cancer Res*. 58(10):2095-2097.
- Oliva E, 2006. Metastatic tumors to the female genital tract, with emphasis to metastatic tumors to the ovary, In: CD Symposia IAP, Montreal
- Palacios J, 2005. Metastatic tumors of the female genital tract, In: European Congress of Pathology. Carrefour Pathologie 2005. Update in Pathology, Paris, pp. 165-167
- Palacios J, Catusus L, Moreno-Bueno G, Matias-Guiu X, Prat J, Gamallo C., 2001. β - and γ -catenin expression in endometrial carcinoma. Relationship with clinicopathological features and microsatellite instability. *Virchows Arch*. 438(5):464-469.
- Palacios J, Gamallo C, 1998. Mutations in the beta-catenin gene (CTNNB1) in endometrioid ovarian carcinomas. *Cancer Res*. 58(7):1344-1347.
- Pavelic ZP, Pavelic L, Pavelic K, Peacock JS, 1991. Utility of anti-carcinoembryonic antigen monoclonal antibodies for differentiating ovarian adenocarcinomas from gastrointestinal metastasis to the ovary. *Gynecol Oncol*. 40(2):112-117.
- Pinkel D, Segraves R, Sudar D, Clark S, Poole I, Kowbel D, Collins C, Kuo W-L, Chen C, Zhai Y, Dairkee SH, Ljung B-m, Gray JW, Albertson DG, 1998. High resolution analysis of DNA copy number variation using comparative genomic hybridization. *Nat Genet*. 20(2):207-211.
- Prat J, 2002. Clonality analysis in synchronous tumors of the female genital tract (Editorial). *Hum Pathol*. 33(4): 383-385
- Prat J, 2005. Simultaneous adenocarcinomas of the uterus and ovaries, European Congress of Pathology. Carrefour Pathologie 2005. Update in Pathology, Paris, pp. 158- 162
- Prat J, Matias-Guiu X, Barreto J, 1991. Simultaneous carcinoma involving the endometrium and the ovary. A clinicopathologic, immunohistochemical, and DNA flow cytometric study of 18 cases. *Cancer*. 68(11):2455-2459.
- Prayson RA, Hart WR, Petras RE, 1994. Pseudomyxoma peritonei. A clinicopathologic study of 19 cases with emphasis on site of origin and nature of associated ovarian tumors. *Am J Surg Pathol*. 18(6):591-603.
- Ricci R, Komminoth P, Bannwart F, Torhorst J, Wight E, Heitz PU, Caduff RF., 2003. PTEN as a molecular marker to distinguish metastatic from primary synchronous endometrioid carcinomas of the ovary and uterus. *Diagn Mol Pathol*. 12(2):71-78.
- Risinger JI, Berchuck A, Kohler MF, Watson P, Lynch HT, Boyd J., 1993. Genetic instability of microsatellites in endometrial carcinoma. *Cancer Res*. 53(21):5100-5103.
- Risinger JI, Hayes AK, Berchuck A, Barrett JC., 1997. PTEN/MMAC1 mutations in endometrial cancers. *Cancer Res*. 57(21):4736-4738.
- Risinger JI, Hayes K, Maxwell GL, Carney ME, Dodge RK, Barrett JC, Berchuck A., 1998. PTEN mutation in endometrial cancers is associated with favorable clinical and pathologic characteristics. *Clin Cancer Res*. 4(12):3005-3010.
- Robboy SJ, Scully RE, Norris HJ, 1974. Carcinoid metastatic to the ovary. A clinicopathologic analysis of 35 cases. *Cancer*. 33(3):798-811
- Rodriguez IM, Prat J, 2002. Mucinous tumors of the ovary: A clinicopathologic analysis of 75 borderline tumors (of intestinal type) and carcinomas. *Am J Surg Pathol*. 26(2):139-152.
- Ronnett BM, 2002. Endometrial Carcinoma. In: Kurman, RJ (Ed.) Blaustein's pathology of the female genital tract, fifth edition, Springer, pp. 501-560
- Ronnett BM, 2006. Synchronous and Metachronous Appendiceal and Ovarian Mucinous Tumors, CD Symposia IAP, Montreal

- Ronnett BM, Kajdacsy-Balla A, Gilks CB, Merino MJ, Silva E, Werness BA, Young RH, 2004. Mucinous borderline ovarian tumors: points of general agreement and persistent controversies regarding nomenclature, diagnostic criteria, and behavior. *Hum Pathol.* 35(8):949-960.
- Ronnett BM, Kurman RJ, Shmookler BM, Sugarbaker PH, Young RH, 1997a. The morphologic spectrum of ovarian metastases of appendiceal adenocarcinomas. A clinicopathologic and immunohistochemical analysis of tumors often misinterpreted as primary ovarian tumors or metastatic tumors from other gastrointestinal sites. *Am J Surg Pathol.* 21(10):1144-1155.
- Ronnett BM, Kurman RJ, Zahn CM, Shmookler BM, Jablonski KA, Kass ME, Sugarbaker PH., 1995a. Pseudomyxoma peritonei in women: A clinicopathologic analysis of 30 cases with emphasis on site of origin, prognosis, and relationship to ovarian mucinous tumors of low malignant potential. *Hum Pathol.* 26(5):509-524.
- Ronnett BM, Seidman JD, 2003. Mucinous tumors arising in ovarian mature cystic teratomas: relationship to the clinical syndrome of pseudomyxoma peritonei. *Am J Surg Pathol.* 27(5):650-657.
- Ronnett BM, Shmookler BM, Diener-West M, Sugarbaker PH, Kurman RJ, 1997b. Immunohistochemical evidence supporting the appendiceal origin of pseudomyxoma peritonei in women. *Int J Gynecol Pathol.* 16(1):1-9.
- Ronnett BM, Yan H, Kurman RJ, Shmookler BM, Wu L, Sugarbaker PH, 2001. Patients with pseudomyxoma peritonei associated with disseminated peritoneal adenomucinosis have a significantly more favorable prognosis than patients with peritoneal mucinous carcinomatosis. *Cancer.* 92(1):85-91.
- Ronnett BM, Zahn CM, Kurman RJ, Kass ME, Sugarbaker PH, Shmookler BM, 1995b. Disseminated peritoneal adenomucinosis and peritoneal mucinous carcinomatosis. A clinicopathologic analysis of 109 cases with emphasis on distinguishing pathologic features, site of origin, prognosis, and relationship to "pseudomyxoma peritonei". *Am J Surg Pathol.* 19(12):1390-1408.
- Rudzki Z, Zazula M, Bialas M, Klimek M, Stachura J, 2002. Synchronous serrated adenoma of the appendix and high-grade ovarian carcinoma: a case demonstrating different origin of the two neoplasms. *Pol J Pathol.* 53(1):29-34
- Rusell P, Bannatyne PM, Solomon HJ, Stoddard LD, Tattersall MH., 1985. Multifocal tumorigenesis in the upper female genital tract: Implications for staging and management. *Int J Gynecol Pathol.* 4(3):192-210
- Rutgers JL, Scully RE, 1988. Ovarian müllerian mucinous papillary cystadenomas of borderline malignancy. A clinicopathologic analysis. *Cancer.* 61(2): 340-348.
- Saegusa M, Okayasu I, 2001. Frequent nuclear/beta-catenin accumulation and associated mutations in endometrioid type endometrial and ovarian carcinomas with squamous differentiation. *J Pathol.* 194(1):59-67.
- Sato N, Tsunoda H, Nishida M, Morishita Y, Takimoto Y, Kubo T, Noguchi M., 2000. Loss of heterozygosity on 10q23.3 and mutation of the tumor suppressor gene PTEN in benign endometrial cyst of the ovary: possible sequence progression from benign endometrial cyst to endometrioid carcinoma and clear cell carcinoma of the ovary. *Cancer Res.* 60(24):7052-7056.
- Schlosshauer PW, Pirog EC, Levine RL, Ellenson LH., 2000. Mutation analysis of the CTNNB1 and APC gene in uterine endometrial carcinoma. *Mod Pathol.* 13(10):1066-1071.
- Scully RE, Young RH, Clement PB, 1998. Tumors of the ovary, maldeveloped gonads, fallopian tube, and broad ligament. *Atlas of Tumor Pathology, 3rd series (Rosai, J Ed.)*. Washington, D.C.: American Registry of Pathology.
- Seidman JD, Elsayed AM, Sobin LH, Tavassoli FA, 1993. Association of mucinous tumors of the ovary and appendix. A clinicopathologic study on 25 cases. *Am J Surg Pathol.* 17(1):22-34.
- Seidman JD, Kurman RJ, Ronnett BM, 2003. Primary and metastatic mucinous adenocarcinomas in the ovaries: incidence in routine practice with a new approach to improve intraoperative diagnosis. *Am J Surg Pathol.* 27(5):985-993.
- Shannon C, Kirk J, Barnetson R, Evans J, Schnitzler M, Quinn M, Hacker N, Crandon A, Harnett P. 2003. Incidence of microsatellite instability in synchronous tumors of the ovary and endometrium. *Clin Cancer Res.* 9(4):1387-1392.
- Shenson DL, Gallion HH, Powell DE, Pieretti M., 1995. Loss of heterozygosity and genomic instability in synchronous endometrioid tumors of the ovary and endometrium. *Cancer.* 76(4):650-657.
- Smale L, 1980. Metastatic breast adenocarcinoma to Brenner tumors. *Gynecol Oncol.* 9(2):251-253.
- Smit VT, Cornelisse CJ, De Jong D, Dijkshoorn NJ, Peters AA, Fleuren GJ., 1988. Analysis of tumor heterogeneity in a patient with synchronously occurring female genital tract malignancies by DNA flow cytometry: DNA fingerprint and immunohistochemistry. *Cancer.* 62(6):1146-1152.
- Snidjers A, Nowak N, Segraves R, Blackwood S, Brown N, Conroy J, Hamilton G, Hindle AK, Huey B, Kimura K, Law S, Myambo K, Palmer J, Ylstra B, Yue JP, Gray JW, Jain AN, Pinkel D, Albertson DG., 2001. Assembly of microarrays for genome-wide measurement of DNA copy number. *Nat Genet.* 29(3):263-240.
- Stewart CJ, Brennan BA, Hammond IG, Leung YC, McCartney AJ., 2005. Accuracy of frozen section in distinguishing primary ovarian neoplasia from tumors metastatic to the ovary. *Int J Gynecol Pathol.* 24(4):356-362.
- Sumithran E, Susil BJ, 1992. Concomitant mucinous tumors of appendix and ovary: Result of a neoplastic field change? *Cancer.* 70(12):2980-2983.
- Szych C, Staebler A, Connolly DC, Wu R, Cho KR, Ronnett BM, 1999. Molecular genetic evidence supporting the clonality and appendiceal origin of pseudomyxoma peritonei in women. *Am J Pathol.* 154(6):1849-1855.

- Tashiro H, Blazes MS, Wu R, Cho KR, Bose S, Wang SI, Li J, Parsons R, Ellenson LH., 1997. Mutations in PTEN are frequent in endometrial carcinoma but rare in other common gynecological malignancies. *Cancer Res.* 57(18):3935-3940.
- Tavassoli FA, Devilee P, 2003. World Health Organization Classification of Tumors, Pathology and genetics. Tumours of the breast and female genital organs, IARC Press, Lyon
- Tornos C, Soslow R, Chen S, Akram M, Hummer AJ, Abu-Rustum N, Norton L, Tan LK., 2005. Expression of WT1, CA 125, and GCDFP-15 as useful markers in the differential diagnosis of primary ovarian carcinomas versus metastatic breast cancer to the ovary. *Am J Surg Pathol.* 29(11):1482-1489.
- Ulbright TM, Roth LM, 1985. Metastatic and independent cancers of the endometrium and the ovary: a clinicopathologic study of 34 cases. *Hum Pathol.* 16(1):28-34.
- Vang R, Gown AM, Barry TS, Wheeler DT, Ronnett BM, 2006b. Cytokeratins 7 and 20 in primary and secondary mucinous tumors of the ovary: analysis of coordinate immunohistochemical expression profiles and staining distribution in 174 cases. *Am J Surg Pathol.* 30(9):1130-1139.
- Wa CV, DeVries S, Chen YY, Waldman FM, Hwang ES., 2005. Clinical application of array-based comparative genomic hybridization to define the relationship between multiple synchronous tumors. *Modern Pathol.* 18(4):591-597.
- Woodruff JD, Julian CG, 1969. Multiple malignancy in the upper genital canal. *Am J Obstet Gynecol.* 103(6): 810-822.
- Yakushiji M, Tazaki T, Nishimura H, Kato T, 1987. Krukenberg tumors of the ovary: a clinicopathologic analysis of 112 cases. *Acta Obstet Gynaecol Jpn.* 39(3):479-485
- Young RH, Gersell DJ, Clement PB, Scully RE, 1992. Hepatocellular carcinoma metastatic to the ovary: a report of three cases discovered during life with discussion of the differential diagnosis of hepatoid tumors of the ovary. *Hum Pathol.* 23(5): 574-580.
- Young RH, Gilks CB, Scully RE, 1991. Mucinous tumors of the appendix associated with mucinous tumors of the ovary and pseudomyxoma peritonei. A clinicopathological analysis of 22 cases supporting an origin in the appendix. *Am J Surg Pathol.* 15(5):415-429.
- Young RH, Hart WR, 1998a. Metastases from carcinomas of the pancreas simulating primary mucinous tumors of the ovary. A report of seven cases. *Am J Surg Pathol.* 13(9):748-756.
- Young RH, Hart WR, 1998b. Metastatic intestinal carcinomas simulating primary ovarian clear cell carcinoma and secretory endometrioid carcinoma: a clinicopathologic and immunohistochemical study of five cases. *Am J Surg Pathol* 1998;22(7):805-815.
- Young RH, Path FRC, Scully RE, 2002. Metastatic tumors of the ovary. In: Blaustein's pathology of the female genital tract, fifth edition, (editor Kurman RJ), Springer, pp. 1063-1101
- Young RH, Scully RE, 1990. Ovarian metastases from carcinoma of the gallbladder and extrahepatic bile ducts simulating primary tumors of the ovary. A report of six cases. *Int J Gynecol Pathol.* 9(1):60-72.
- Young RH, Scully RE, 1991. Metastatic tumors in the ovary: a problem-oriented approach and review of the recent literature. *Semin Diagn Pathol.* 8(4):250-276.
- Zaino RJ, Unger ER, Whitney C, 1984. Synchronous carcinomas of the uterine corpus and ovary. *Gynecol Oncol.* 19(3):329-335.

1 "Gr. T. Popa" University of Medicine and Pharmacy, Iasi, Romania

2 "Alexandru Ioan Cuza" University, Iasi, Romania

* cornelia.amalinei@histo-m.umfiiasi.ro, cornelia_amalinei@yahoo.com