

NEUROFIBROMATOSIS TYPE 1 – MOLECULAR TESTING AND CLINICAL PRESENTATION OF TWO CASES

CRISTINA GUG^{1,2,*}, ANDREI ANGHEL³, LIVIU TAMAȘ³, EDWARD ȘECLĂMAN³, PATRICK WILLEMS⁴

Keywords: neurofibromatosis type 1, mutation NF1 gene, premature stop codon, truncated NF1 protein

Abstract: Neurofibromatosis type 1 is caused by mutations in the NF1 gene located on chromosome 17q. Case 1: A 1 year 7-month-old boy had progressive right ptosis which began when he was 19 months of age and numerous café-au-lait spots. Case 2: A 28 years old woman presents: café-au-lait spots, one subcutaneous tumor on the left leg, a first degree family member, who has NF1-malignant form. Molecular Genetic analysis consisted of: 1. Amplification of the entire coding region of the NF1 gene. 2. Screening for deletions and duplications in the NF1 gene by MLPA analysis. Results: Case 1: A heterozygous c.1719delT mutation was identified in exon 11 of the NF1 gene. Case 2: A heterozygous c.6709C>T mutation was identified in exon 45 of the NF1 gene. Conclusions: The mutations founded in both cases determined a truncated NF1 protein, which is disease-causing.

INTRODUCTION

Neurofibromatosis 1 (NF1), also known as von Recklinghausen syndrome, is one of the most common genetic diseases, characterized by skin anomalies and fibromatosis tumors. It is an autosomal dominant disorder with complete penetrance (Mattocks C., et al., 2004). Neurofibromatosis type 1 is the most common cancer predisposition syndrome with an estimated birth incidence of about 1 in 3500 individuals worldwide (Gutmann 2001). Approximately 15–20% of patients with NF-1 will develop Optic Glioma, sometimes as the first sign (Erbay S. H. et al., 2004). Neurofibromatosis type 1 is caused by mutations in the NF1 gene located on chromosome 17q. The NF 1 gene is large (295 kilobases and 61 exons, 4 exons being in alternative transcripts – 9a, 10a-2, 23a and 48a) and codes for four alternatively spliced transcripts. NF1 is unusual in that one of its introns contains coding sequences for at least three other genes. The NF1 gene product, neurofibromin, a protein of 2818 aminoacids is ubiquitously expressed and is present at low concentration in many tissues, with its highest levels of expression found in cells of the central nervous system, where it is usually associated with tubulin. Neurofibromin displays partial homology to GTPase-activating protein (GAP) and appears to activate ras GTPase, thereby controlling cellular proliferation and acting as a tumor suppressor but its functions are not fully understood (Messiaen L, et al., 2000). The NF1 gene product, neurofibromin, displays partial homology to GTPase-activating protein (GAP). The aim of this study was the identification of the mutation in the NF1 gene on the two patients with Neurofibromatosis 1. This situation has allowed the confirmation of the clinical diagnosis and the establishment of a way to manage the cases from there on, with the purpose of having a molecular prenatal diagnosis for a future pregnancy

MATERIALS AND METHODS

The diagnosis of NF1 is made in an individual with any two of the following clinical features (Table 1): café-au-lait spots, neurofibromas, plexiform neurofibromas, freckling in the axillary or inguinal regions, Lisch nodules (iris haematomas), optic or chiasma glioma, distinctive bone lesions (pseudoarthrosis, and sphenoid dysplasia) and first degree family relative with NF1 (Cohen R, Shuper A. 2010).

The NF1 patient should fulfill 2 or more of the following criteria	
1.	Six or more café au lait macules <ul style="list-style-type: none">• diameter \geq 1.5 cm in postpubertal individuals• \geq 0.5 cm in prepubertal individuals
2.	Two or more neurofibromas of any type, or one plexiform neurofibroma
3.	Multiple freckles in the axillary area or groin
4.	Optic glioma
5.	Two or more Lisch nodules (hamartomas of iris)
6.	A distinct osseous lesion, such as

The NF1 patient should fulfill 2 or more of the following criteria	
	<ul style="list-style-type: none"> • sphenoid dysplasia • thinning of the long bone cortex with or without pseudoarthrosis
7.	A first-degree relative (parent, sibling, or offspring) who meets the above criteria for NF1

Table 1. Diagnostic criteria for NF1 (Gutmann et al. 1997).

We describe two patients with clinical characteristics suggestive for Neurofibromatosis 1.

Case 1: A 1 year 7-month-old boy had progressive right ptosis which began when he was 19 months of age and numerous café-au-lait spots. The main symptom was painless proptosis, developed in the last two months. Ophthalmologic examination showed reduced visual acuity (down to 25%) due to optic atrophy. It was not observed nystagmus due to compress of the optic chiasm. MRI of brain at 20 months age revealed the presence of optic glioma, at the right optic nerve. In this family this child is the first person affected (Fig 1).

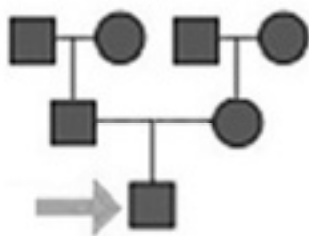


Fig 1: Pedigree for case 1.

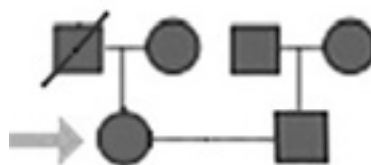


Fig. 2. Pedigree for case 2.

Case 2: A 28 years old woman (Fig. 2) presents: about 10 flat, oval, café-au-lait spots, more than 1.5 cm in diameter (Fig. 3), axillary freckling (Fig. 4), one subcutaneous tumor on the left leg (Fig. 5), and some degree of scoliosis; a first degree family member (father), who has NF1 - spinal neurofibromatosis malignant form – deceased of this cause.

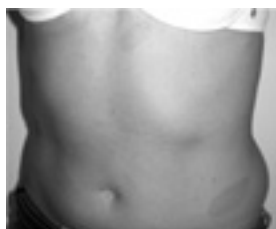

Fig. 3. Case 2: Patient presents oval, café-au-lait spots, more than 1.5 cm in diameter,

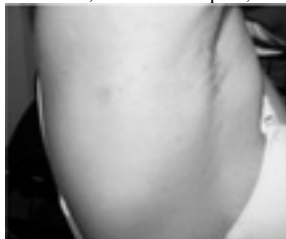

Fig. 4. Case 2: Patient presents axillary freckling.

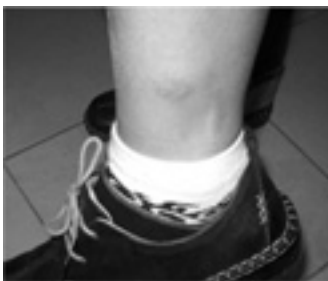

Fig. 5. Case 2: Patient presents one subcutaneous tumor on the left leg

Genetic analysis consisted of:

1. PCR amplification of the entire coding region of the NF1 gene (exons 1-58), including the intron-exon boundaries, was followed by the screening of the PCR products by DGGE. PCR products with a positive DGGE signal were further analyzed by sequencing. Alternatively spliced exons (exons 9a, 10a-2 and 48a) were not analyzed, but no mutation has ever been reported in over 500 NF1 patients tested for these exons. The reference sequence and exon numbering is according to Ensembl ENST 00000358273 with the 'A' of the ATG start codon at position 1.

2. Screening for deletions and duplications in the NF1 gene by MLPA analysis which identifies deletions/duplications not detectable by sequence analysis of genomic DNA. Deletions of part of the NF1 gene as well as deletions and duplications of the complete NF1 gene have been described. The deletion of a 1500 kb chromosomal region that includes the complete NF1 gene is somewhat common (5-10% of NF1 cases). The MLPA analysis was performed using SALSA MLPA kit P081 NF1 mix 1 and SALSA MLPA kit P082 NF1 mix 2 (MRC-Holland) according to manufacturer's protocol.

RESULTS AND DISCUSSIONS

Café-au-lait spots and neurofibromas are defining features of neurofibromatosis 1 (NF1), but they vary greatly in number, size, and clinical importance from patient to patient. The cause of this variability is unknown (Palmer C, et al., 2004). Case 1 had three signs of disease and case 2 had two signs. In the case of NF1, no clear links between genotype and phenotype have been found, and the severity and specific nature of the symptoms may vary widely among family members with the disorder (Korf and Rubenstein 2005). The disease manifestations are extremely variable, even within a family.

No deletion/duplication was identified by MLPA analysis in both cases, more than 90% of the NF1 gene mutations being point mutations.

Case 1: A heterozygous c.1719delT mutation was identified in exon 11 of the NF1 gene (Fig.6). This frame shift mutation creates a premature stop codon on position 585 (p.Ser574fsX585). The mutation results in a truncated NF1 protein. The c.1719delT mutation is a novel mutation not previously described in other patients nor in controls. Tumors of the central nervous system are frequent. Optic nerve glioma (also known as optic pathway glioma) is the most common primary neoplasm of the optic nerve, usually affects younger patients with clinical symptoms in one third of cases. MRI shows fusiform enlargement with variable enhancement of the optic nerve. These tumors are usually non-aggressive with good prognosis. Other gliomas and astrocytomas can occur as well, usually midline in location, and also generally have good prognosis (Jacques C, Dietemann JL. 2005). From 10 to 38% of pediatric patients with optic nerve glioma have NF-1; conversely, 15-40% of children with NF-1 have optic nerve glioma. Our 1-year-7-month-old boy patient had progressive unilateral right ptosis with a rapid evolution (two months). Bilateral optic nerve gliomas are almost pathognomonic for NF-1 (Listernick R, et al., 1989). In general benign optic glioma grows relatively slowly, if at all, over extended

periods, however, some lesions can progress, causing visual impairment, so ongoing follow-up has been recommended (Thiagalingam S, et Al., 2004). The patient did not present nystagmus, situation that mainly occurs when a large lesion may compress the optic chiasm. In extensive Hypothalamic lesions symptoms such as changes in appetite or sleep may also occur. Massive lesions may compress the third ventricle, resulting in obstructive hydrocephalus accompanied by headache, nausea, and vomiting (Tumialan LM, et al., 2005), (Taylor T et al. 2008).

Local surgical therapy for large lesions may cause significant morbidity, including hypothalamic dysfunction. The decision has been made that surgical intervention was not to be performed at that time. Another form, aggressive glioma, is most common in adults; it is frequently fatal, even with treatment (Wilhelm H. 2009).

The molecular analysis of the parents proved the “de novo” origin of the mutation of their child. Half of affected individuals have NF1 as the result of a new gene NF1 mutation (Pinson S, Wolkenstein P., 2005). The parents decided to perform prenatal molecular analysis at the next pregnancy.




Fig. 6. Gene NF 1: In case 1 the mutation was identified in exon 11 and in case 2 the mutation was identified in exon 36, but a frame shift mutation creates a premature stop codon.

Case 2: A heterozygous $c.6709C>T$ mutation was identified in exon 36 of the NF1 gene (Fig. 6.). This mutation leads to replacement of an arginine by a premature stop codon on position 2237 of the protein (p.Arg2237X). The $c.6709C>T$ mutation was previously described in other patients, and some studies have shown that this mutation is found in more than 0,5% of NF1 patients. A recent study on a cohort of 1,770 unrelated patients identified 1,017 different NF1 mutations. 813 out of these 1,017 mutations were singular mutations, indicating that 46% of the patients (813/1,770) carry a “private mutation” (Wimmer K, et al., 2006).

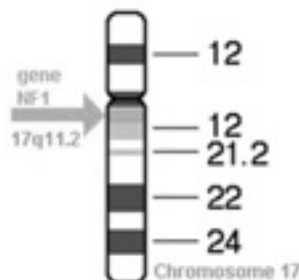


Fig. 7. Gene NF 1 localised at 17q11.2

The NF1 gene maps to chromosome 17q11.2 (Fig. 7) and is thought to be a tumor suppressor gene because loss of heterozygosity is associated with the occurrence of benign and malignant tumors in tissues derived from the neural crest (Mattocks et al. 2004). Neurofibromin (a GTPase activating enzyme), the protein products of the normal *nf1* gene, acts as a tumor suppressor and limits cell growth. Mutation in this gene leads to cell overgrowth and an increased risk of developing benign and malignant tumor (Cohen R, Shuper A. 2010). The affected individuals develop both benign and malignant tumors at an increased frequency.

In case 1 the patient developed optic glioma and in case 2 a first degree family member (the patient's father), who has NF1 - spinal neurofibromatosis malignant form – has deceased of this cause. Neurofibrosarcoma is the main cause of death of NF1 patients less than 40 years of age. It may develop de novo or from sarcomatous degeneration of a pre-existing plexiform neurofibroma (Jacques C, Dietemann JL. 2005).

The diagnosis of neurofibromatosis 1 is usually based on clinical findings. Neurofibromatosis 1, one of the most common Mendelian disorders, is caused by heterozygous mutations of the NF1 gene. Almost one half of all affected individuals have de novo mutations. Molecular genetic testing is available clinically but is infrequently needed for diagnosis (Jett K, Friedman JM. 2010). The importance of molecular testing refers to calculating the recurrence risk within the family and prenatal diagnosis. In our study, evaluating the first case has proven recurrence risk to future pregnancies to be very small, due to the fact that the patient's parents are healthy and they do not have the mutation. The parents will continue molecular testing on their next pregnancy in order to exclude the risk of a possible germinal mosaicism.

Since the original National Institutes of Health consensus Development Conference in 1987, there has been significant progress towards a more complete understanding of the molecular bases for neurofibromatosis 1 and the routine follow-up for the care of the NF1 patients (Pinson S, Wolkenstein P., 2005).

Jett K, Friedman JM. (2010) recommended annual physical examination by a physician familiar with the disorder. Other recommendations include ophthalmologic examinations annually in children and less frequently in adults, regular developmental assessment in children, regular blood pressure monitoring, and magnetic resonance imaging for follow-up of clinically suspected intracranial and other internal tumors.

CONCLUSIONS

The mutations founded in both cases determined a truncated NF1 protein, which is disease-causing. The importance of molecular testing refers to calculating the recurrence risk within the family and prenatal diagnosis. Functional analyses of mutations in the NF1 gene may provide further insights into the pathogenesis of NF1 tumors.

REFERENCES

- Cohen R, Shuper A. (2010) *Developmental manifestation in children with neurofibromatosis type 1* Harefuah. Jan;149(1):49-52, 61. {Journal Article}
- Erbay S. H., Stephen A. Oljeski S. O., Bhadelia R. *Rapid Development of Optic Glioma in a Patient with Hybrid Phakomatosis: Neurofibromatosis Type 1 and Tuberous Sclerosis* American Journal of Neuroradiology 25:36-38, January 2004 {Journal Article}
- de Goede-Bolder A, Cnossen MH, Dooijes D, van den Ouweland AM, Niermeijer MF. (2001) *From gene to disease; neurofibromatosis type 1*. Ned Tijdschr Geneesk. Sep 8;145(36):1736-8. {Journal Article}

- Gutmann DH, Aylsworth A, Carey JC, Korf B, Marks J, Pyeritz RE, Rubenstein A, Viskochil D. (1997) *The diagnostic evaluation and multidisciplinary management of neurofibromatosis 1 and neurofibromatosis 2*. JAMA. Jul 2;278(1):51-7. {Journal Article}
- Gutmann DH. (2001) *The neurofibromatoses: when less is more*. Hum Mol Genet. Apr;10(7):747-55. {Journal Article}
- Jacques C, Dietemann JL. (2005) *Imaging features of neurofibromatosis type 1*. J Neuroradiol. Jun;32(3):180-97. {Journal Article}
- Jett K, Friedman JM. (2010) Genet Med. *Clinical and genetic aspects of neurofibromatosis 1*. Jan;12(1):1-11. {Journal Article}
- Listernick R, Charrow J, Greenwald MJ, et al. (1989) *Optic gliomas in children with neurofibromatosis type 1*. J Pediatr. May;114(5):788-92 {Journal Article}
- Mattocks C., Baralle D., Tarpey P., French-Constant C., Bobrow M., Whittaker J., (2004) *Automated comparative sequence analysis identifies mutations in 89% of NF1 patients and confirms a mutation cluster in exons 11–17 distinct from the GAP related domain*. J Med Genet ;41:e-48. {Journal Article}
- Messiaen L, Callens T, Mortier G, Beysen D, Vandembroucke I, et al: (2000), *Exhaustive mutation analysis of the NF1 gene allows identification of 95% of mutations and reveals a high frequency of unusual splicing defects*. Hum Mutat;15:541–555. {Journal Article}
- Palmer C, Szudek J, Joe H, Riccardi VM, Friedman JM. (2004) *Analysis of neurofibromatosis 1 (NF1) lesions by body segment*. Am J Med Genet A. Mar 1;125A(2):157-61. {Journal Article}
- Pinson S, Wolkenstein P. (2005) *Neurofibromatosis type 1 or Von Recklinghausen's disease*. Rev Med Interne. Mar;26(3), 196-215 {Journal Article}.
- Taylor T, Jaspan T, Milano G, Gregson R, Parker T, Ritzmann T, et al. (2008) *Radiological classification of optic pathway gliomas: experience of a modified functional classification system*. Br J Radiol.Oct 81(970):761-6. {Journal Article}
- Thiagalingam S, Flaherty M, Billson F. (2004) *Neurofibromatosis type 1 and optic pathway gliomas: follow-up of 54 patients*. Ophthalmology. Mar 111(3):568-77. {Journal Article}
- Tumialan LM, Dhall SS, Biousse V. (2005) *Optic nerve glioma and optic neuritis mimicking one another: case report*. Neurosurgery. Jul;57(1):E190; . {Journal Article}
- Wilhelm H. (2009) *Primary optic nerve tumours*. Curr Opin Neurol. Feb;22(1):11-8. {Journal Article}
- Wimmer K, Yao S, Claes K, Kehrer-Sawatzki H, Tinschert S, et al: (2006) *Spectrum of single- and multiexon NF1 copy number changes in a cohort of 1,100 unselected NF1 patients*. Genes Chromosomes Cancer;45:265–276. {Journal Article}

-
- 1 Department of Medical Genetics, University of Medicine and Pharmacy “Victor Babeș”, Timișoara, Romania
2 Genetics Medical Center “Dr. Cristina Gug”, Timișoara, Romania
3 Department of Biochemistry, University of Medicine and Pharmacy “Victor Babeș”, Timișoara, Romania
4 Gendia, Antwerp, Belgium

* Cristina Gug, “CABINET MEDICAL ȘI LABORATOR DE GENETICĂ DR. CRISTINA GUG”, Timișoara, Splaiul Tudor Vladimirescu nr.1, C.P. 300193. Mobil: 0742038240, 0723552516, Telefon fix cabinet: 0256-200895, Telefon fix acasă 0256-482232. Mail: dr.cristina.gug@gmail.com