

## A SEMIQUANTITATIVE ANALYSIS TECHNIQUE REGARDING IMMUNOHISTOCHEMICAL DETECTION FOR MATRIX METALLOPROTEINASES

TUDOR PETREUȘ<sup>1\*</sup>, CATALINA TEODORA PINTILIE<sup>2</sup>,  
CARMEN ELENA COTRUTZ<sup>1</sup>, LUCIAN GORGAN<sup>3</sup>,  
MONICA NEAMȚU<sup>1</sup>, ANDREI NEAMȚU<sup>1</sup>

**Keywords:** matrix metalloproteinases, immunohistochemistry, color deconvolution

**Abstract:** Modern image processing techniques are used today in order to evaluate immunohistochemical detection for various markers, especially those important for malignant tumor diagnosis and remodeling processes. Evaluating the immunohistochemical markers detection may be completed by a quantitative analysis. We have used samples of normal and fibrous tissue from surgical scars harvested after 2 months from surgery. We have investigated the immunohistochemically marked areas and we have performed a semiquantitative image analysis, using an academic, open sourcesoftware, ImageJ v. 1.38. After image adjustments (binarization) and correction, we have applied a deconvolution filter after which we have performed and analyzed a histogram of the selected area. The binarized areas were measured and compared for three samples of each tissue. We have followed the semiquantitative analysis of MMP-2 and MMP-9 presence on the investigated samples. This technique, even if controversial, allows us a fast analysis of common markers detected by immunohistochemistry

### INTRODUCTION

Modern image processing techniques are used today in order to evaluate immunohistochemical detection for various markers, especially those important for malignant tumor diagnosis and remodeling processes. Evaluating the immunohistochemical markers detection may be completed by a quantitative analysis. However, due to difficult access to these markers and the reduced amount of tissue that can be harvested, we can use complementary techniques for image processing that may allow us to better quantify tumor markers detection by immunohistochemistry [1].

Matrix metalloproteinases (MMPs) are a family of zinc-containing endoproteinases that have been traditionally characterized by their collective ability to degrade all components of the extracellular matrix [2]. These enzymes are postulated to regulate the homeostasis of a variety of tissues under the control of tissue inhibitor of metalloproteinases (TIMPs), which bind to and inhibit the activity of MMPs. Accordingly, an imbalance between MMPs and TIMPs can lead to a variety of pathological states, such as metastasis of cancer [3], or diseases including, rheumatoid arthritis and multiple sclerosis.

In the 60s, Cross and Lapiere [4], were the first to describe the collagenolytic activity responsible for tadpole resorption. In 2010 there are 28 well defined classes of MMP, most of them are involved in human health and diseases. Cell-matrix interactions are critical for cells and tissue behaviors during normal development and also for pathological processes including benign and malignant tumors. MMPs are essential regulators for signals represented by matrix molecules involved in cell growth and development. Uncontrolled remodeling induced by MMP overexpression or malfunction result in abnormal development and induction of many pathological conditions in which excessive degradation or a lack of degradation of ECM components occurs [5,6].

The MMPs can be divided into collagenases (MMP-1, -8, -13, and -18), gelatinases (MMP-2 and -9), stromelysins (MMP-3, -10, and -11), and membrane-type MMPs (MMP-14, -15, -16, and -17). For more than 30 years MMPs have been seen as promising targets for the treatment of the above-mentioned diseases because collagenase (MMP-1), gelatinases (MMP-2 and -9), and stromelysin-I (MMP-3) have been shown to play a key role in cancer invasion and metastasis [7].

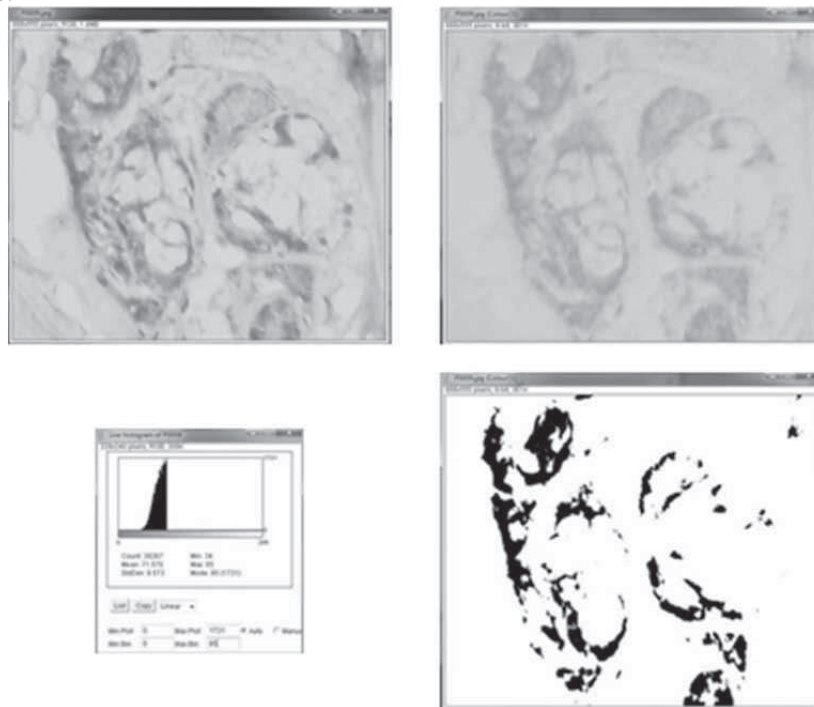
### MATERIAL AND METHODS

We have used samples of normal and fibrous tissue from surgical scars harvested after 2 months from surgery. MMP2 and 9 were detected by immunohistochemical means with DAB-labeled antibodies. We have investigated the immunohistochemically marked areas and we have performed a semiquantitative image analysis, using an academic, open sourcesoftware, ImageJ v. 1.38.

This technique was imagined and applied by Ruifrok and Johnston; it evaluates the intensity of the immunohistochemical labeling for any color less than grey. The images were captured at the same size in pixels, 3264x2448 pixels, in RGB color coding system. We have selected 3 areas following pathologist advice in order to avoid large vessels. After image adjustments (binarization) and correction, we have applied a deconvolution filter after which we have performed and analyzed a histogram of the selected area.

## RESULTS

The binarized areas were measured and compared for three samples of each tissue. We have followed the semiquantitative analysis of MMP-2 and MMP-9 presence on the investigated samples. For each sample we have followed the same protocol for three regions of interest on the same slide.



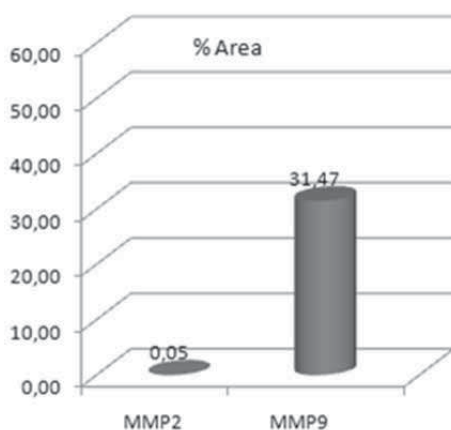
**Figure 1.** MMP9 detection, histogram and colour deconvolution for DAB

The final results expressed as ratios of marked areas for the two investigated antiMMP DAB-labeled antibodies are shown in table 1 and figure 2.

**Table 1.** Percent areas for MMP2 and MMP9, detected by immunohistochemistry

	MMP2	MMP9
C1	0,245	38,092
	0,056	10,623
	0,249	16,722

	<b>MMP2</b>	<b>MMP9</b>
<b>Mean case C1</b>	<b>0,18</b>	<b>21,81</b>
C2	0	22,02
	0	27,457
	0	7,428
<b>Mean case C2</b>	<b>0,00</b>	<b>18,97</b>
C3	0	29,649
	0	23,265
	0	4,085
<b>Mean case C3</b>	<b>0,00</b>	<b>19,00</b>
C4	0	94,759
	0	73,904
	0	29,632
<b>Mean case C4</b>	<b>0,00</b>	<b>66,10</b>



**Figure 2.** Graphic representation for the final results, MM2 and MMP9 detection expressed in percentage area

MMP2 appears to be expressed in insignificant amounts in the investigated scar tissues (percent marked areas - 0,05%). Even if it is actively involved in remodeling processes and similar as molecular structure with MMP9, MMP2 levels are really low in the investigated samples. This fact can be due to an important expression of TIMP2 that have inhibited pericellular MMP2. By comparison, MMP9 presence occupies 31,47% surface area.

### CONCLUSIONS

As a conclusion, remodeling processes in scar tissues depend on presence and activity of MMP9 and not on MMP2 presence.

This technique itself, even if controversial, allows us a fast analysis of common markers detected by immunohistochemistry.

## REFERENCES

- Ruifrok, A.C., Johnston, D.A., (2001): *Quantification of histochemical staining by color deconvolution*. Anal Quant Cytol Histol, 23, 291-299.
- Woessner, JF Jr, (1994): *The family of matrix metalloproteinases*. Ann. N.Y. Acad. Sci., 732, 11-21
- Egeblad, M., Werb, Z., (2002): *New functions for the matrix metalloproteinases in cancer progression*. Nat. Rev. Cancer, 2, 161-174.
- Gross, J., Lapiere, C.M., (1962): *Collagenolytic activity in amphibian tissues: A tissue culture assay*. Proc Natl Acad Sci USA, 48, 1014-1022.
- Chakraborti, T., Das, S., Mandal, M., Mandal, A., Chakraborti, S., (2002): *Role of Ca<sup>2+</sup> dependent matrix metalloprotease-2 in stimulating Ca<sup>2+</sup> ATPase activity under peroxynitrite treatment in pulmonary vascular smooth muscle plasma membrane*. IUBMB Life, 53, 167-173.
- Das, S., Chakraborti, T., Mandal, M., Mandal, A., Chakraborti, S., (2002): *Role of membrane-associated Ca<sup>2+</sup> dependent matrix metalloprotease-2 in the oxidant activation of Ca<sup>2+</sup> ATPase by tertiary butylhydroperoxide*. Mol Cell Biochem, 237, 85-93.
- Nelson, A.R., Fingleton, B., Rothenberg, M.L., Matrisian, L.M., (2000): *Matrix metalloproteinases: Biologic activity and clinical implications*. J. Clin. Oncol., 18, 1135-1149.

<sup>1</sup> “Gr. T. Popa” University of Medicine Iaşi, Dept of Cell and Molecular Biology

<sup>2</sup> ORL Clinic St Spiridon Hospital Iaşi, “Gr. T. Popa” University of Medicine Iaşi

<sup>3</sup> „Al. I. Cuza” Iaşi, Faculty of Biology

\* biotudor@gmail.com

**Acknowledgements:** This paper was supported by the Grant IDEI 2560/2008