

THREE SYNCHRONOUS PRIMARY PELVIC CANCERS – A CASE REPORT –

MIHAI CĂPÎLNA^{1*}, SIMONA CRISTINA RUSU¹,
BELA SZABO¹, CRISTINA MARIAN²,
EDUARD CRAUCIUC³, OVIDIU TOMA⁴, DRAGOȘ CRAUCIUC³

Keywords: pelvic cancer, primary synchronous malignancies

Abstract. The occurrence of synchronous primary gynaecologic malignancies is a relatively common event. However, the occurrence of three different pelvic cancers is very rare. In this report, we describe the clinical, surgical and pathological findings of a patient with synchronous primary malignancies of the fallopian tube, endometrium and sigmoid colon. To our knowledge, it is the first case described in the literature with such an association of primary synchronous cancers.

INTRODUCTION

Synchronous occurrence of endometrial and adnexal (ovarian or tubal) cancer in female genital tract is a well known event in gynecological oncology. They may indicate either metastatic or independent neoplasms and the clinical or therapeutic implications and prognosis are very different in each occasion. Compared to metastatic dual cancer, two simultaneous primary cancers are relatively rare and can be easily recognized if the histologic types of each cancer are different. Even more, the occurrence of a pelvic third cancer is an extremely rare event.

The aetiology of synchronous malignancy is uncertain but it has been postulated that embryologically similar tissues of the female genital tract may develop synchronous neoplasms when simultaneously subjected to carcinogens(1,2).

Recently, we experienced three primary cancers occurring in both tubes, endometrium and sigmoid colon with three different histologic patterns. This case, along with the diagnosis and the treatment of synchronous female genital malignancy, will be briefly reviewed.

MATERIAL AND METHODS

In April 2013, a 61 years old white female, gravida 1, para 0, was referred to our clinic with the diagnosis of endometrial cancer and a possible synchronous ovarian cancer. She was menopausal since age of 50 and she described a vaginal bleeding started 3 months before. Her past medical and surgical histories were relatively unremarkable, but her family history revealed a duodenum cancer for her mother, a colon cancer for her father and a stomach cancer for her grand-father. A clinical and ultrasound examination in March 2013 revealed the uterine origin of bleeding, a normal volume uterus but with a 18 mm thick endometrium with a polyp-like image without apparently myometrial invasion and multiseptated, 111x97x90-mm mass having both solid and cystic components in the right ovary, suggesting malignancy ; the left ovary looked normally. A pelvic computed tomographic scan confirmed the existence of the previously mentioned multiseptated cystic right ovarian mass and minimal ascites in the pelvic cavity. In addition, there were no abnormal findings in the abdominal cavity and thorax, with no extraperitoneal enlarged lymph nodes. She underwent in April 2013 a diagnostic uterine curettage under anesthesia in a private hospital, revealing a grade 3 endometriod adenocarcinoma of the endometrium. The CA-125 was elevated 141.8 U/ml. Routine blood test investigations were normal. The clinical diagnosis was stage IA, grade 3 endometrial carcinoma and a synchronous (primary or metastatic) ovarian cancer.

At laparotomy, a right adnexal tumour involving both tube and ovary, of 11x10x9 cm, but mobile, with smooth surface and both solid and cystic parts was discovered. The frozen section revealed malignant tissue. There was a small amount of ascites in the abdomen. The left ovary

and the uterus appeared normal. On the sigmoid colon, a tumour producing bowel stenosis and a retraction of the serosa, very suggestive for malignancy, was discovered. We performed a total abdominal hysterectomy with bilateral adnexectomy, pelvic and paraaortal lymphadenectomy, total omentectomy, appendectomy, recto-sigmoid colon resection (about 20 cm) and peritoneal biopsies. The whole procedure lasted 275 minutes. There were no intraoperative complications. The postoperative recovery was uneventful, and she was discharged home after hospitalisation for 9 days.

The final pathology report described a high-grade (MD Anderson grading system) serous adenocarcinoma of right adnexa, involving both tube and ovary; its origin could not be detected, but contained different microscopic patterns: solid, papillary, cystic, micropapillary and glands (figure 1).

In the left tube, a high-grade serous adenocarcinoma involving the mucosal and muscular layer, but without serosal involvement was found. The left ovary was microscopically normal. For these reasons, we consider also the right adnexal tumour of tubal origin. The cytology of the ascites revealed malignant cells. There were no metastases into the appendix, peritoneum, omentum and in the 25 from the right and 35 from the left side pelvic and from the 55 paraaortal lymph nodes. Final pathological staging was a high-grade tubal cancer stage pT1cN0.

In the endometrium, an endometrioid type adenocarcinoma grade 3 with mucosal invasion only was found (pT1a grade 3N0) (figure 2).

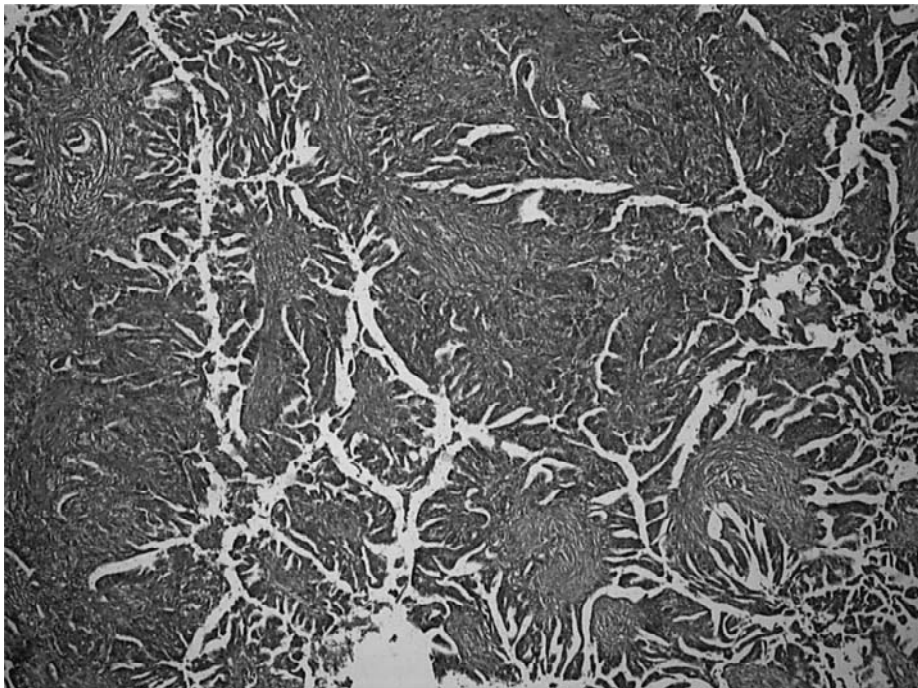


Fig. 1. High-grade (MD Anderson grading system) serous adenocarcinoma of right adnexa, involving both tube and ovary (Hematoxylin-eosine)

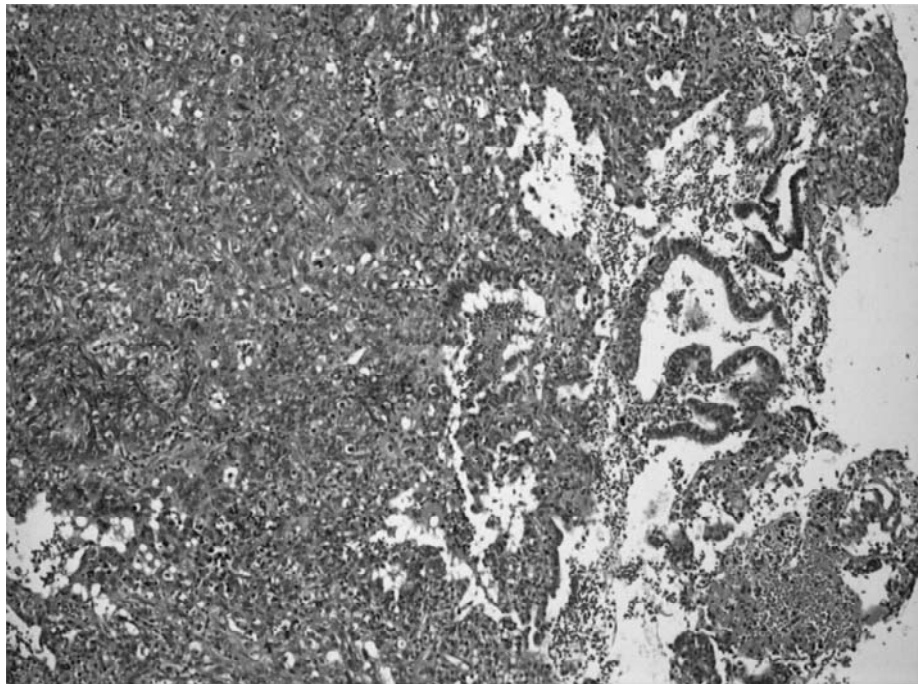


Figure 2. Endometrioid type adenocarcinoma grade 3 (Hematoxylin-eosine)

The third synchronous cancer was a moderate differentiated adenocarcinoma of the recto-sigmoid junction with subserosal invasion without metastases in the 17 regional lymph nodes (pT3N0 Dukes-MACB2) (figure 3).

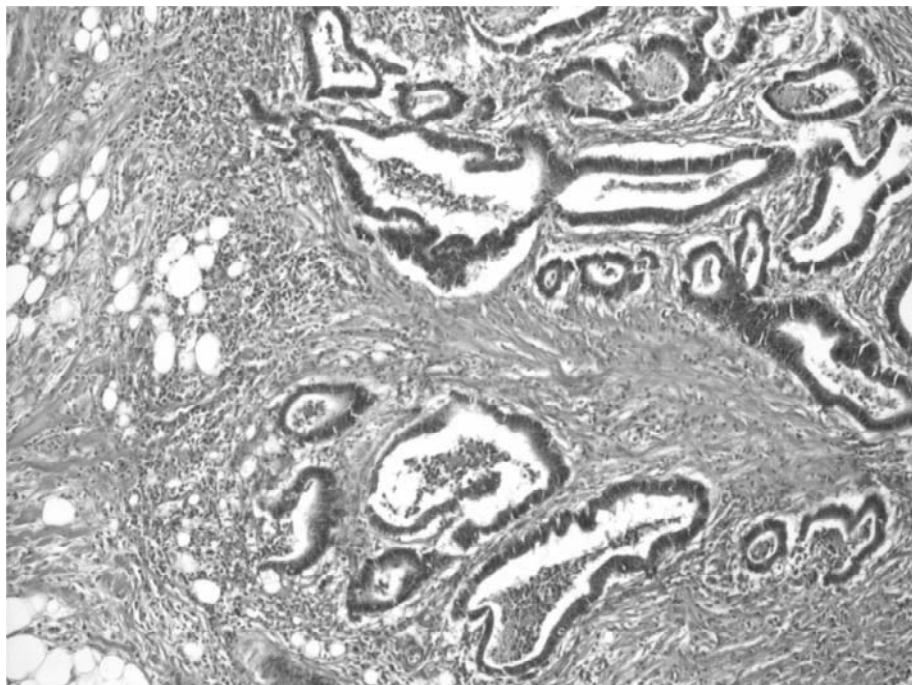


Fig. 3. Moderate differentiated adenocarcinoma of the recto-sigmoid junction with subserosal invasion (Hematoxylin-eosine)

The oncology commission in our hospital decided to start the adjuvant treatment focusing on the tubal cancer. The patient started the Carboplatin/Paclitaxel chemotherapy and she is doing well after four courses.

DISCUSSIONS

The most commonly reported synchronous malignancies were the coexistence of ovarian and endometrial cancers, but genital tract malignancies can arise from more than two anatomical sites, as primary neoplasia. Although the aetiology of synchronous malignancies remains unclear, it has been postulated that the extended mullerian system, comprising ovarian epithelium, fallopian tube, uterus and cervix respond as a single morphological unit to produce primary cancers in different sites. Another theory, which could explain even other sites, suggests that these neoplasm originate in metaplasia occurring in different tissues (4). Till now, limited cases of synchronous primary genital cancers have been reported in the literature, and even less for a third pelvic cancer with an extra-genital origin.

Taking into considerations only 2 cancers out of 3 for our patient (fallopian tube and endometrium), Eisner *et al*(1) described also two synchronous primary cancers of fallopian tube and endometrium, and Atasaver *et al*(8) another 5 sites synchronous cancers involving ovary, both tubes, endometrium and cervix. Our search did not find a similar case in the literature,

comprising 3 synchronous malignancies involving 2 genital sites (tube and endometrium) and another pelvic extra-genital one with different embryologic origin (sigmoid colon).

Our pathologic findings fulfilled the conditions described previously for identification of primary synchronous cancers, such as different histologic types (major criterion) or all the following minor criteria: (1) both tumours confined to primary sites; (2) no direct extension between tumours; (3) no lymphovascular tumour emboli; (4) no or only superficial myometrial invasion; and (5) distant metastases (5, 6, 7).

Simultaneous detection of malignancy in different organs challenges the clinicians and pathologists to make correct diagnosis and arrange proper management (8).

CONCLUSIONS

Appropriate therapy for synchronous cancers must be planned individually. Different parameters such stage, grade, extension, tumour resection margins, etc should be taken into consideration. As a consequence, our oncology staff decided for this special case that most aggressive tumour necessitating first line adjuvant treatment is the high-grade serous adnexal adenocarcinoma.

REFERENCES

1. Eisner RF, Nieberg RK, Berek JS. Synchronous primary neoplasms of the female reproductive tract. *Gynecol Oncol* 1989;33:335—9.
2. Woodruff JD, Solomon D, Sullivant H. Multifocal disease in the upper genital canal. *Obstet Gynecol* 1985;65:695—8.
3. Atasaver M, Yilmaz B, Dilek G, Yilmaz Akcay E, Kelekci S. Synchronous primary carcinoma in 5 different organs of the female genital tract. An unusual case and review of the literature. *Int J Gynecol Cancer* 2009;19: 802-7.
4. Ayhan A, Yalsin OT, Tuncer ZS, et al. Synchronous primary malignancies of the female genital tract. *Eur J Obstet Gynecol Reprod Biol.* 1992;45:63-6.
5. Ulbright TM, Roth LM. Metastatic and independent cancers of the endometrium and ovary: a clinicopathologic study of 34 cases. *Hum Pathol* 1985;16:28—34.
6. Rose PG, Herterick EE, Boutselis JG, Moesberger M, Sachs L. Multiple primary gynecologic neoplasms. *Am J Obstet Gynecol* 1987;157:261—7.
7. Ree YS, Cho SH, Kim SR, Cho SH, Kim KT, Park MH. Synchronous primary endometrial and ovarian cancer with three different histologic patterns. A case report. *Int J Gynecol Cancer* 2003, 13, 678—82.
8. Chang YC, Chen CA, Huang CY, Hsieh CY, Cheng WF. Synchronous primary cancers of the endometrium and ovary. *Int J Gynecol Cancer* 2008, 18, 159-64.

¹ University of Medicine and Pharmacy Târgu-Mureș, Romania, First Clinic of Obstetrics and Gynecology

² University of Medicine and Pharmacy Târgu-Mureș, Romania, Department of Pathology

³ "Gr. T. Popa" University of Medicine and Pharmacy, Iasi, Romania, „Elena Doamna” Iași Clinical Hospital

⁴ "Alexandru Ioan Cuza" University, Iasi, Romania

* mcapilna@gmail.com

